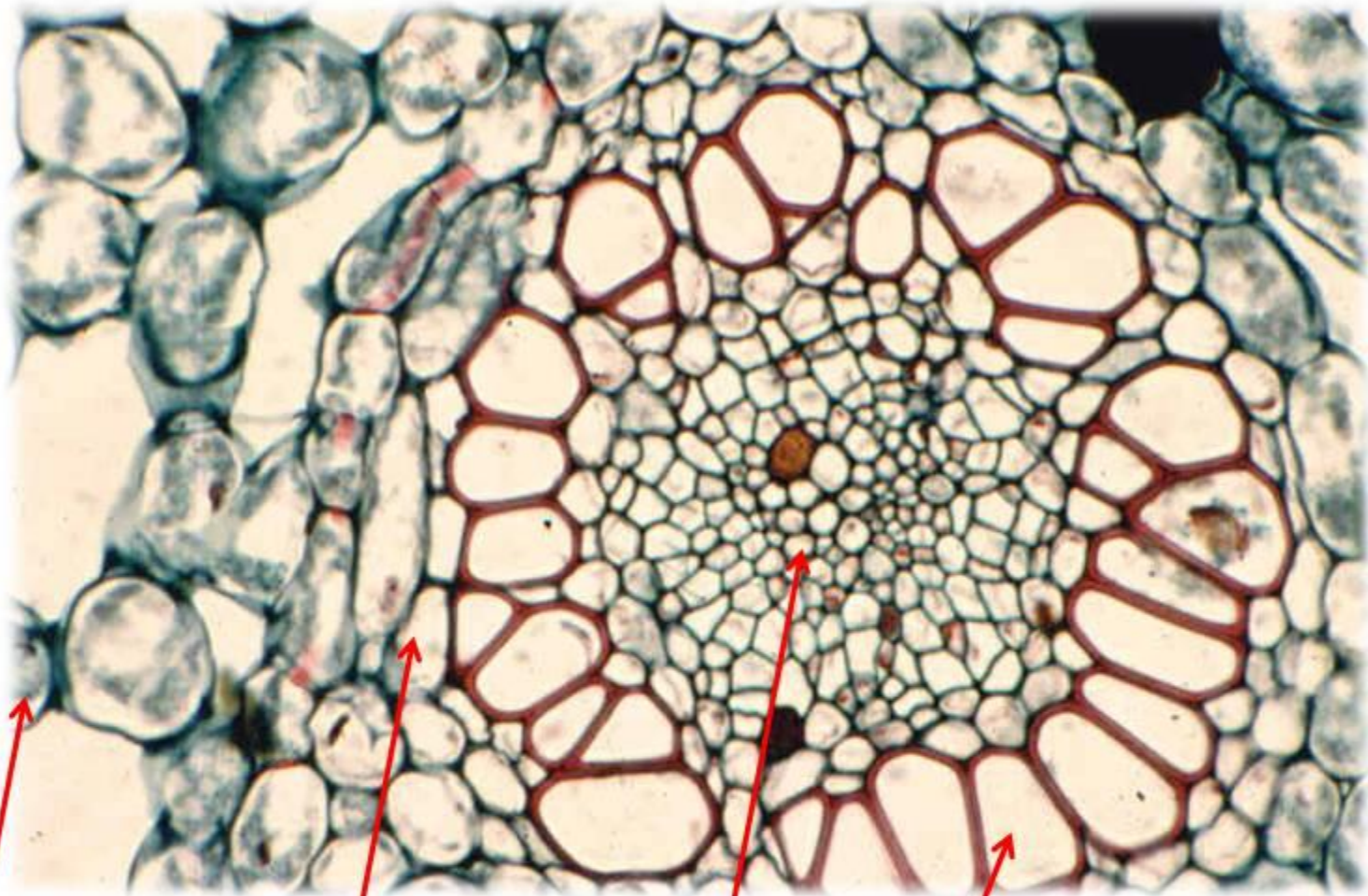

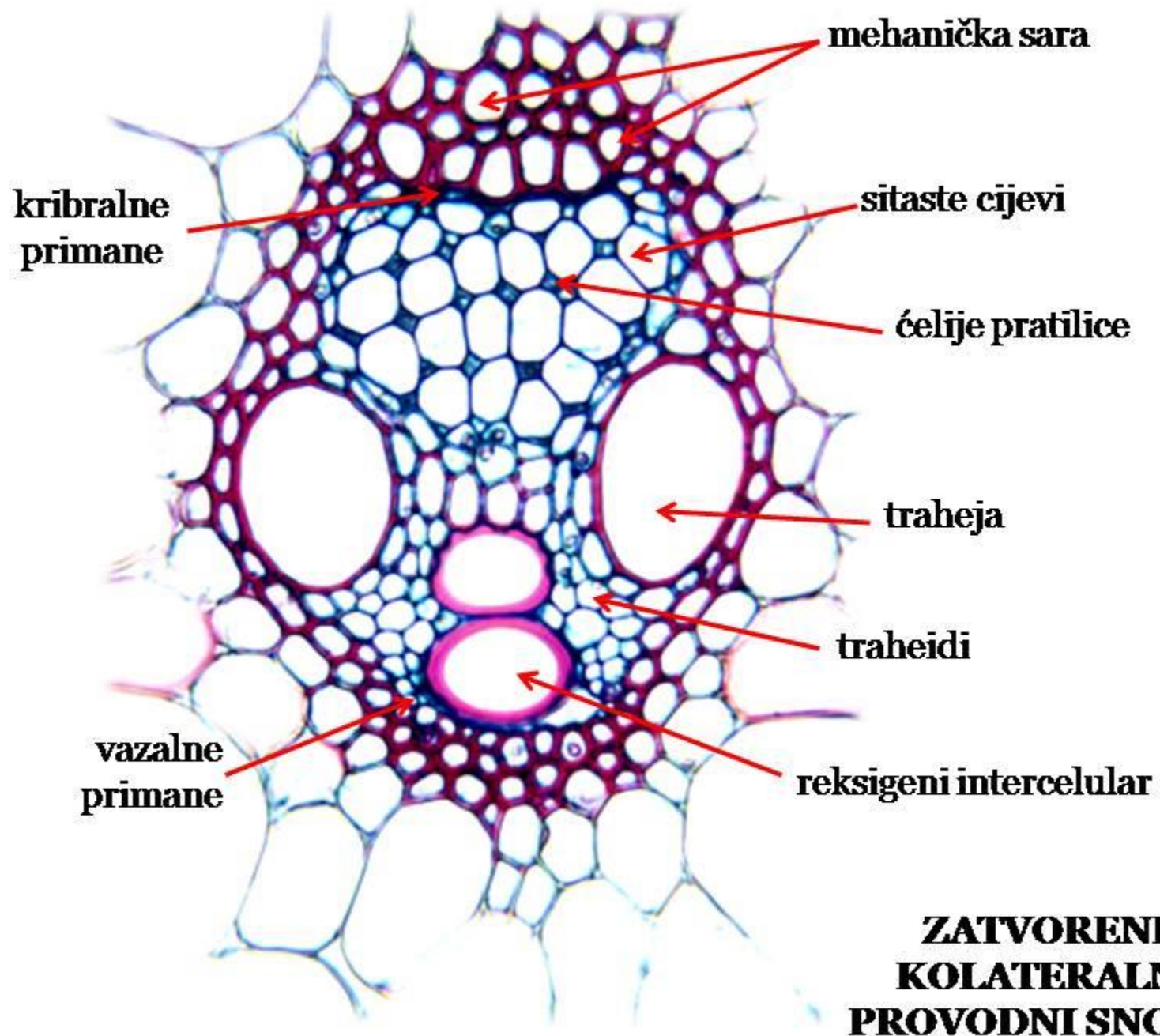
aerenhim
centralnog
cilindra

parenhimska
sara

sitasti
(kribralni)
dio

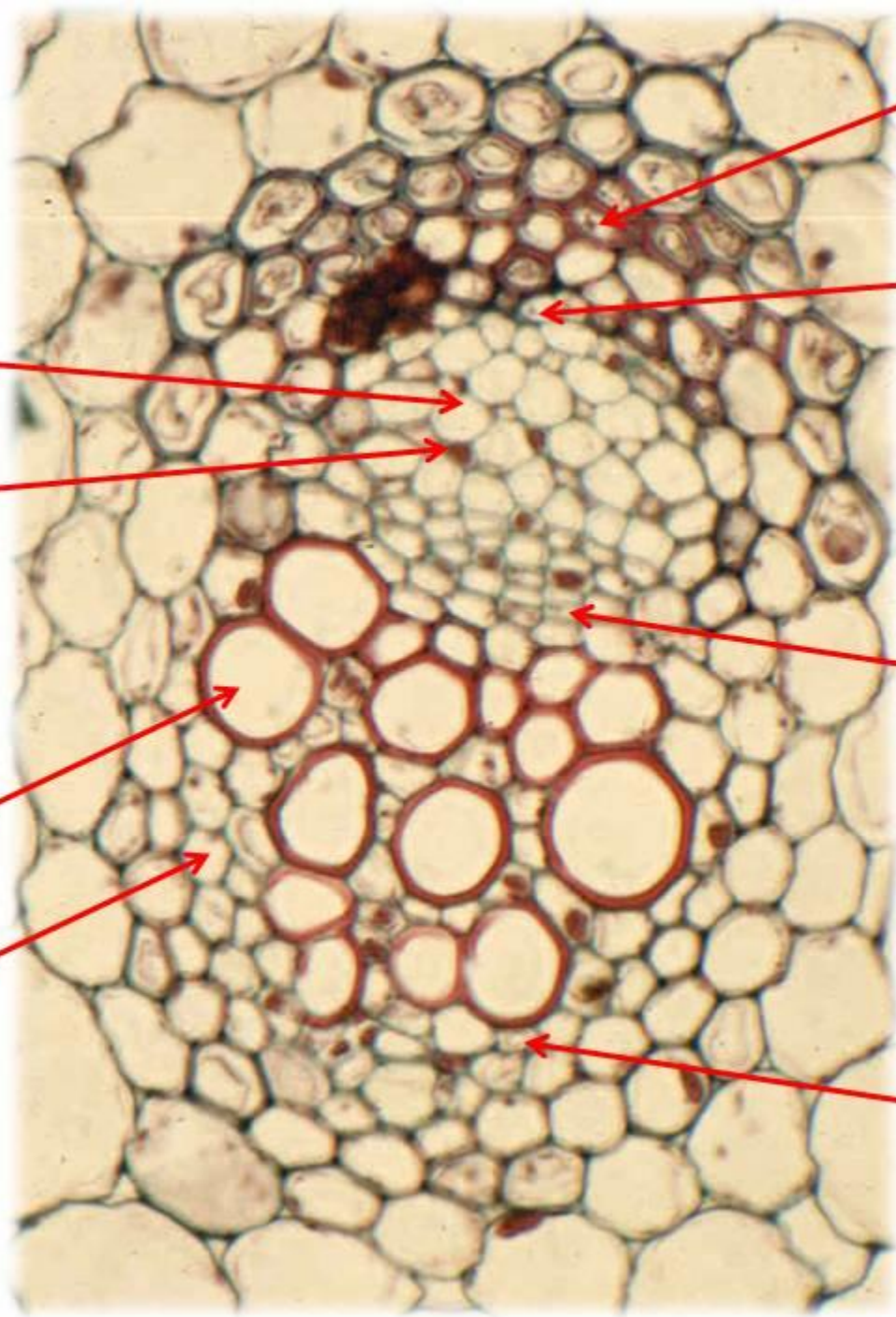
drveni
(vazalni)
dio

**AMFIVAZALNI
PROVODNI
SNOPIĆ**



**ZATVORENI
KOLATERALNI
PROVODNI SNOPIĆ**

**OTVORENI
KOLATERALNI
PROVODNI
SNOPIĆ**



mehanička sara

kribralne primane

sitaste cijevi

ćelije pratilice

kambijum

traheja

traheid

vazalne primane

RADIJALNI PROVODNI SNOPIĆ

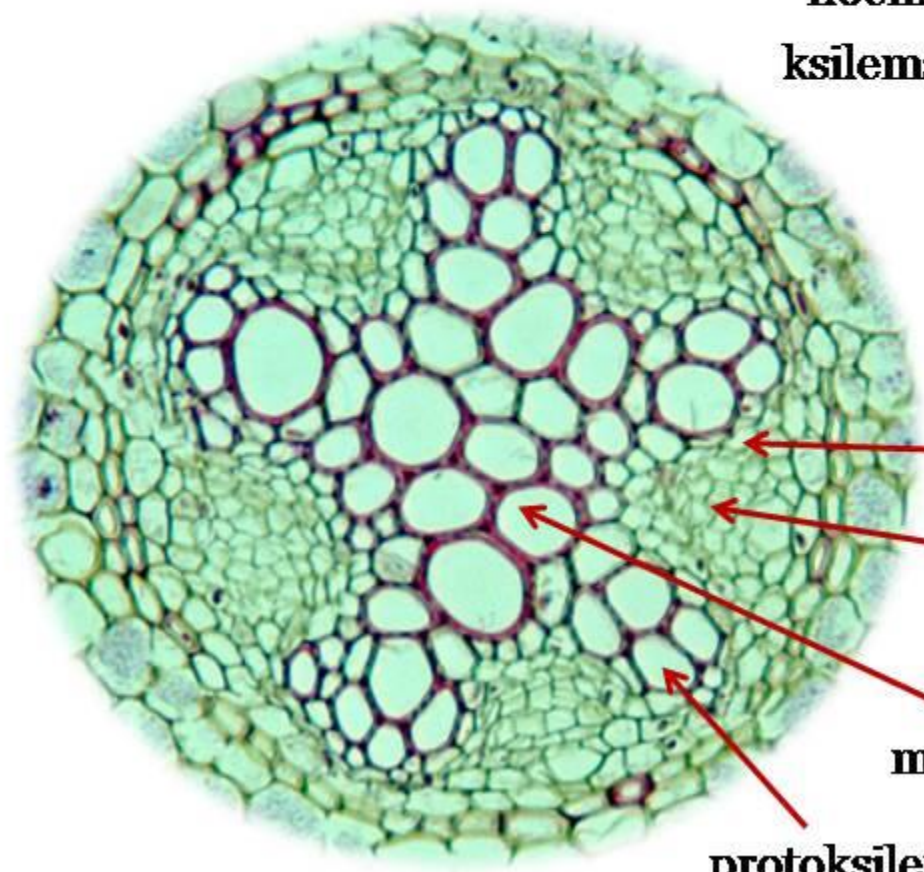
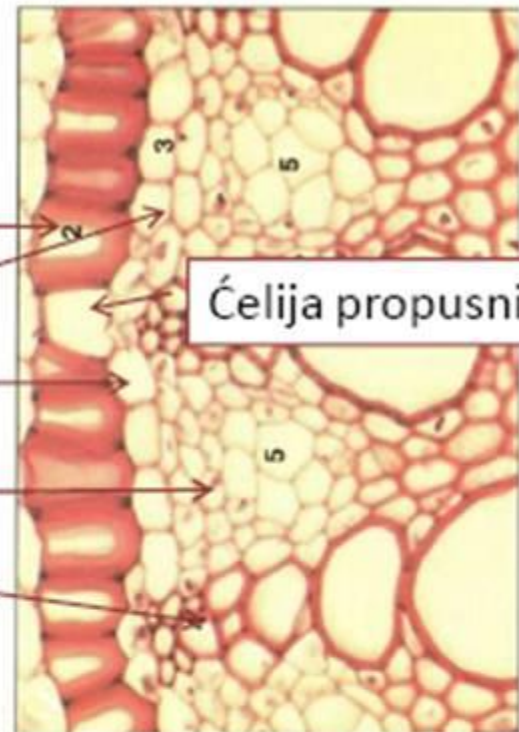
endodermis

pericikl

floemska ploča

ksilemska ploča

Ćelija propusnica



provodni parenhim

floem

metaksilem

protoksilem