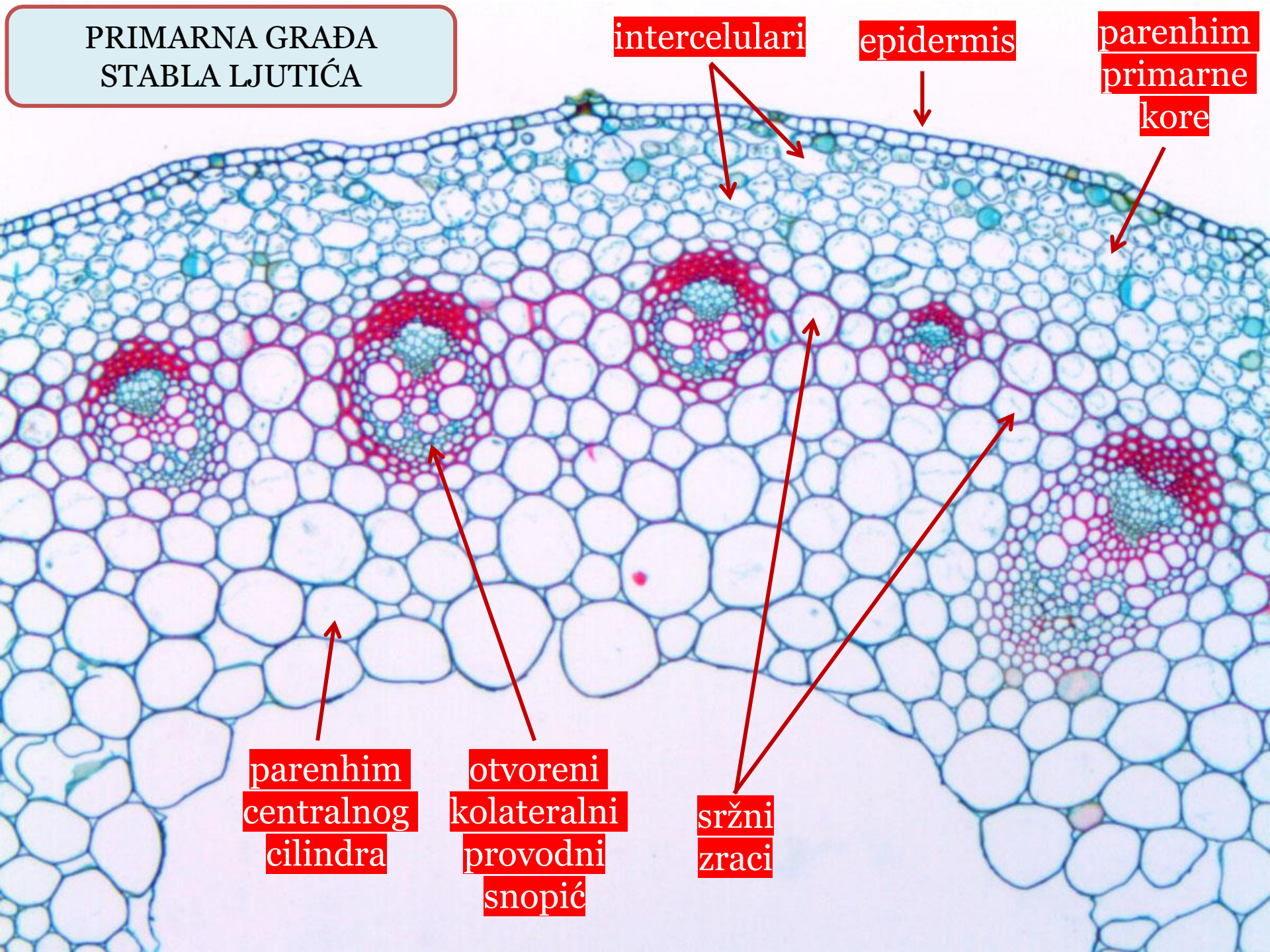


PRIMARNA GRAĐA
STABLA LJUTIĆA



intercelulari

epidermis

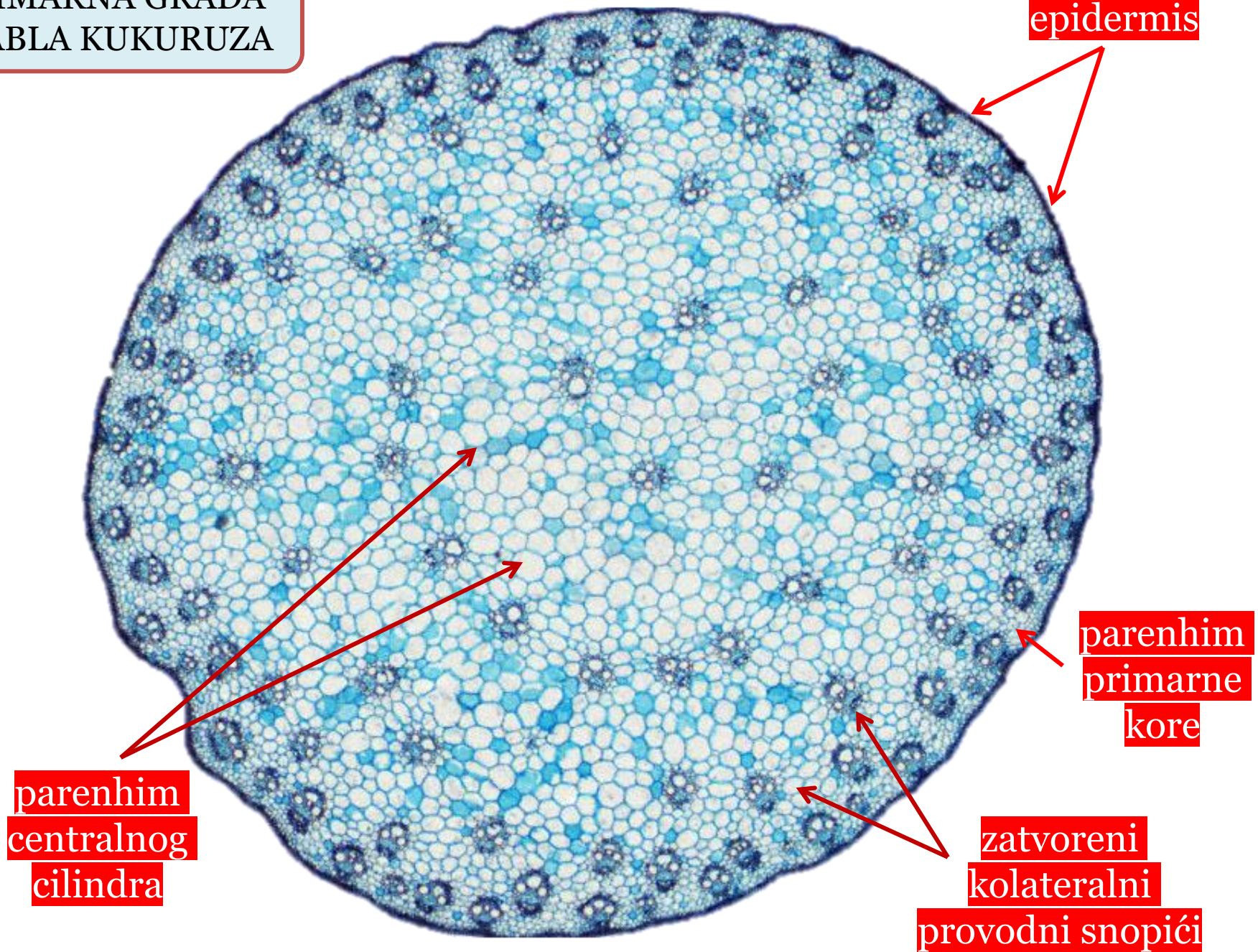
parenhim
primarne
kore

parenhim
centralnog
cilindra

otvoreni
kolateralni
provodni
snopić

sržni
zraci

PRIMARNA GRAĐA
STABLA KUKURUZA



PRIMARNA GRAĐA
KORIJENA PERUNIKE

rizodermis

endodermis

egzodermis

parenhim
primarne
kore

radijalni provodni
snopić (centralni
cilindar)

