

# 10V: Nervno tkivo

## PREPARATI:

- 1) Nervno tkivo kore velikog mozga
- 2) Nervno tkivo kore malog mozga
- 3) Fater-Pačinijev korpuskup
- 4) Ependimske ćelije ventrikularnog sistema mozga

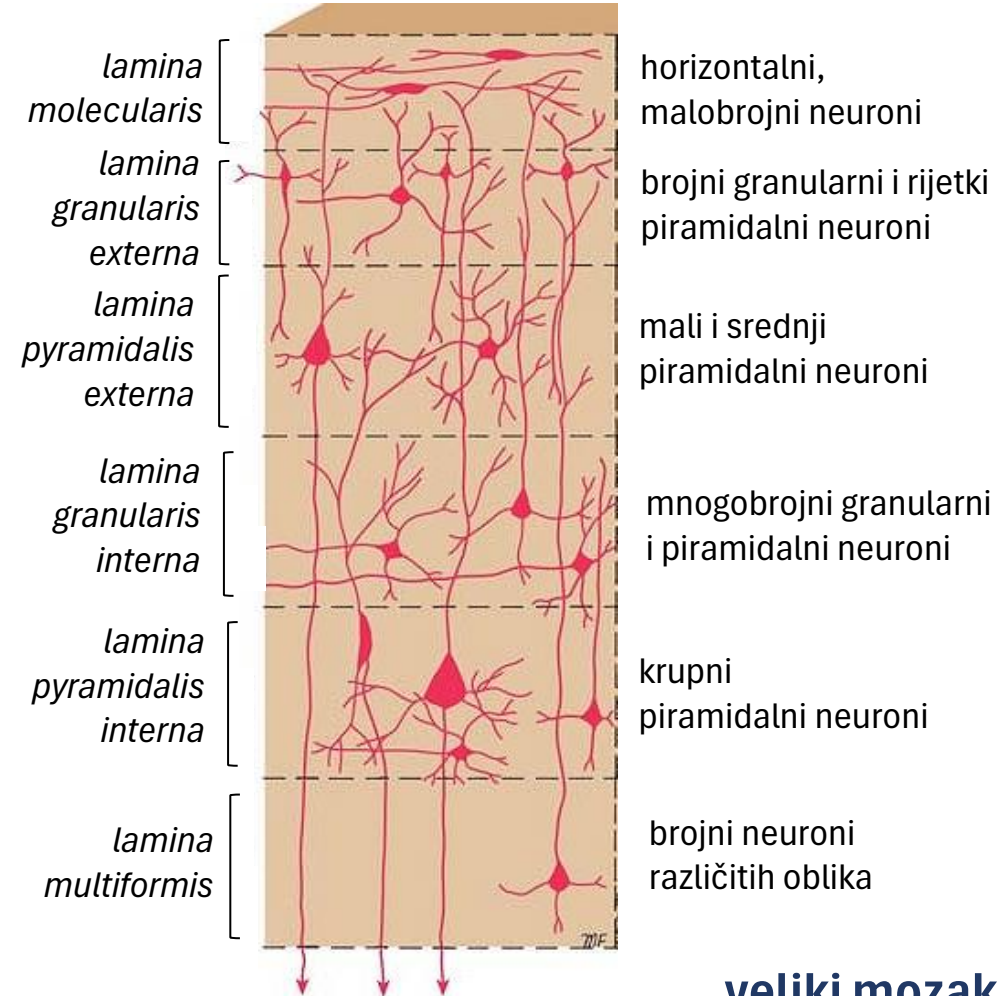
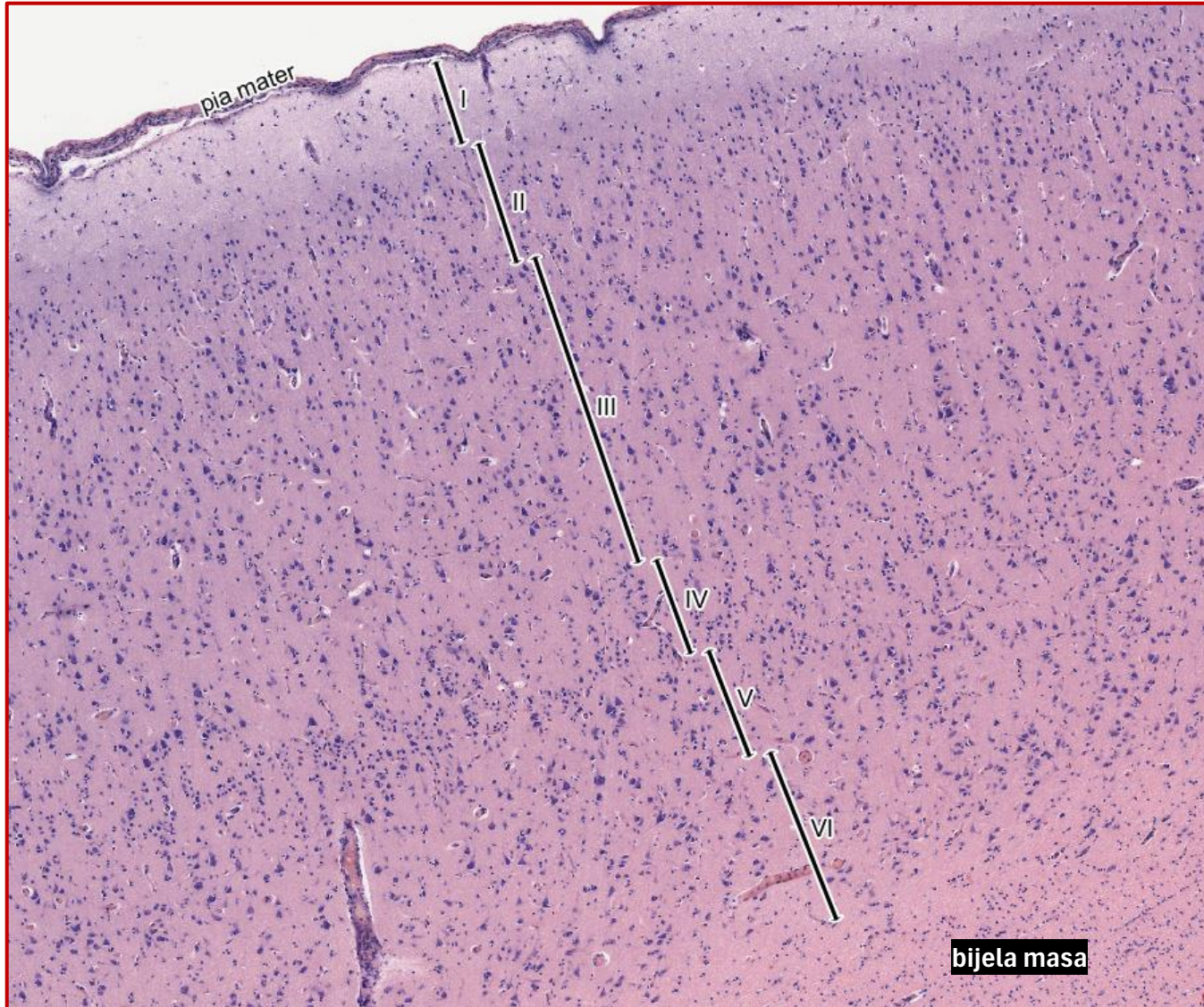Mijat Božović

**CITOLOGIJA I TKIVA**

*materijal za laboratorijske vježbe*

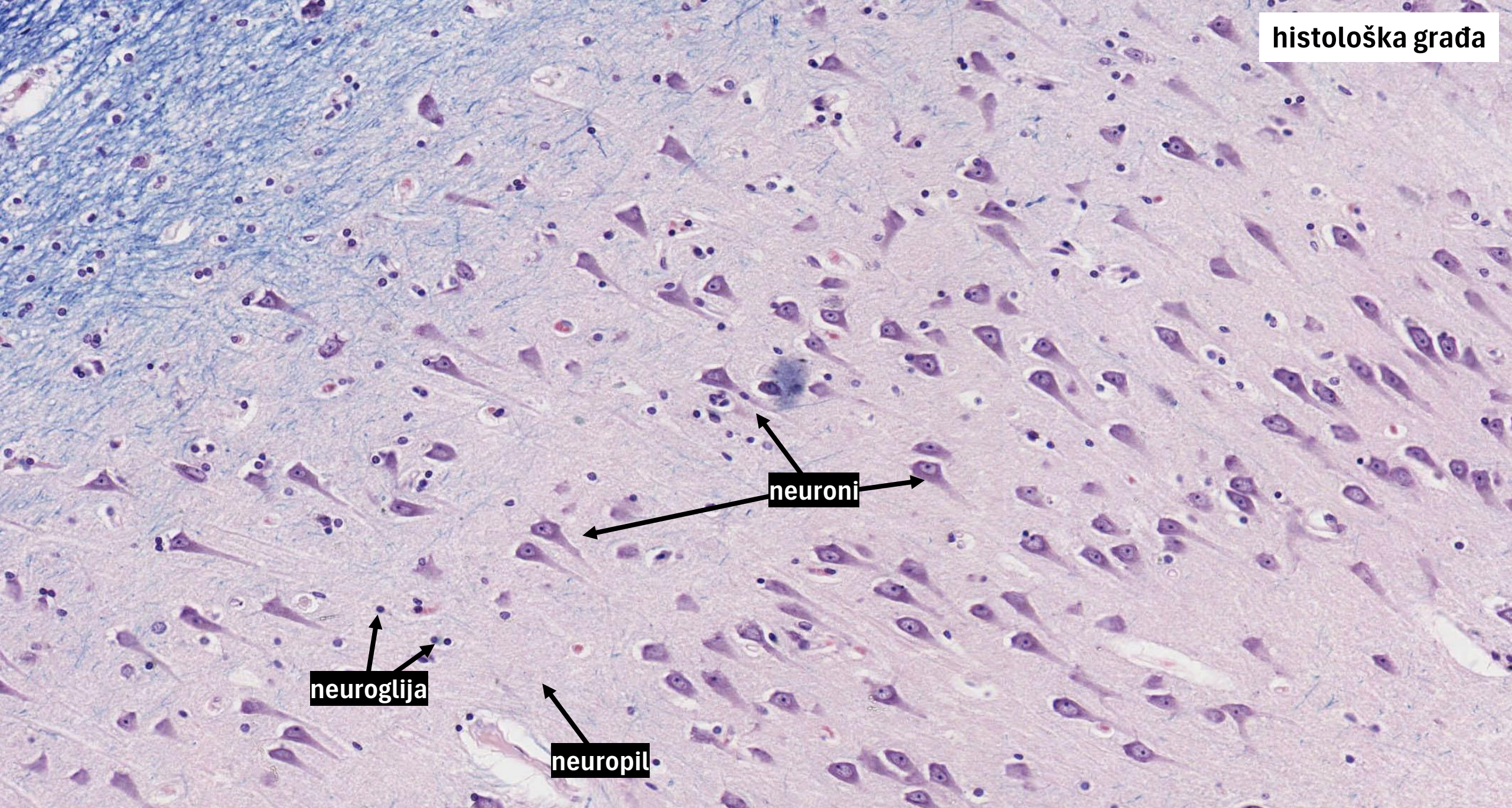


# 1) Nervno tkivo kore velikog mozga



**veliki mozak**  
(*cerebrum*)





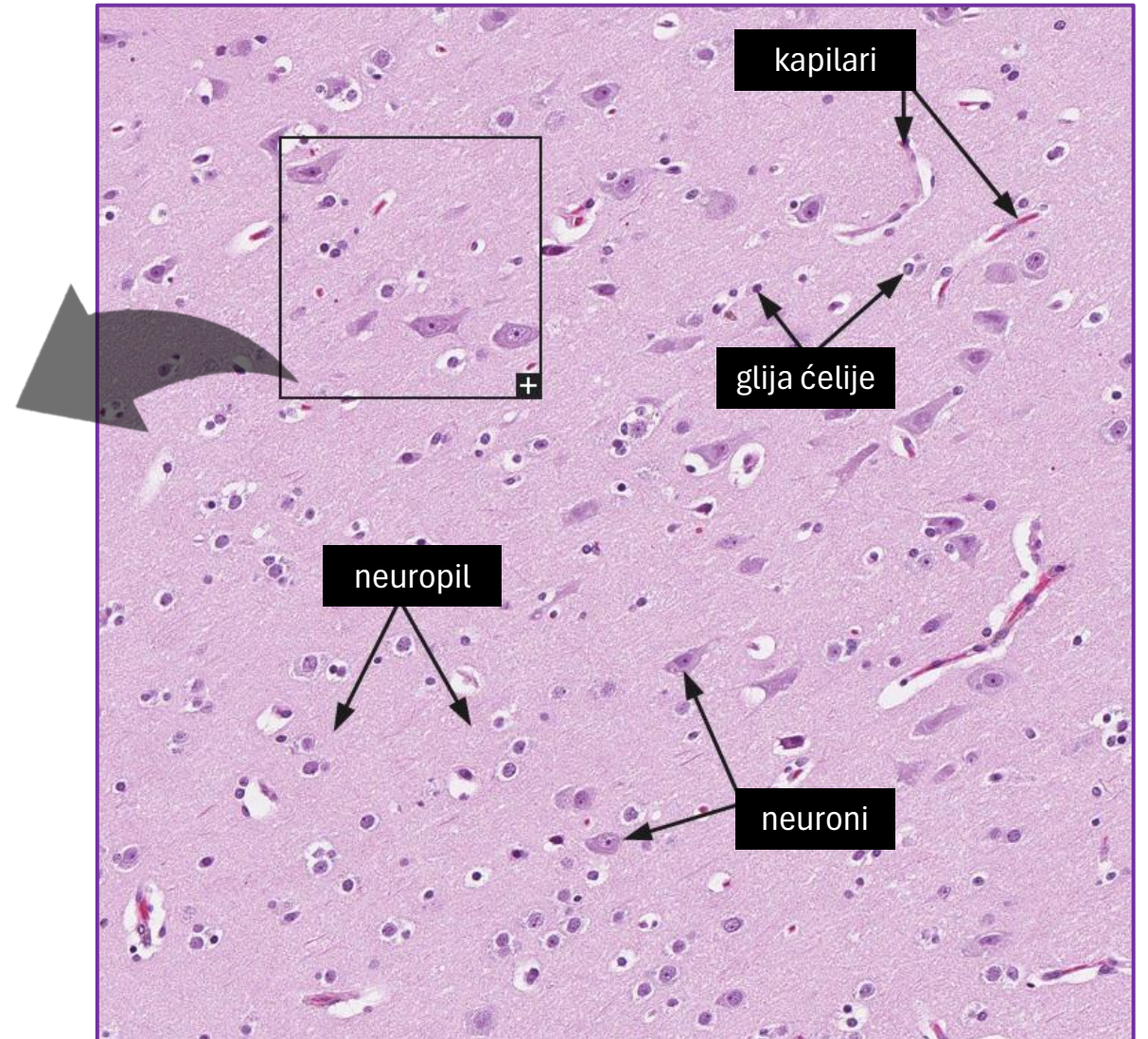
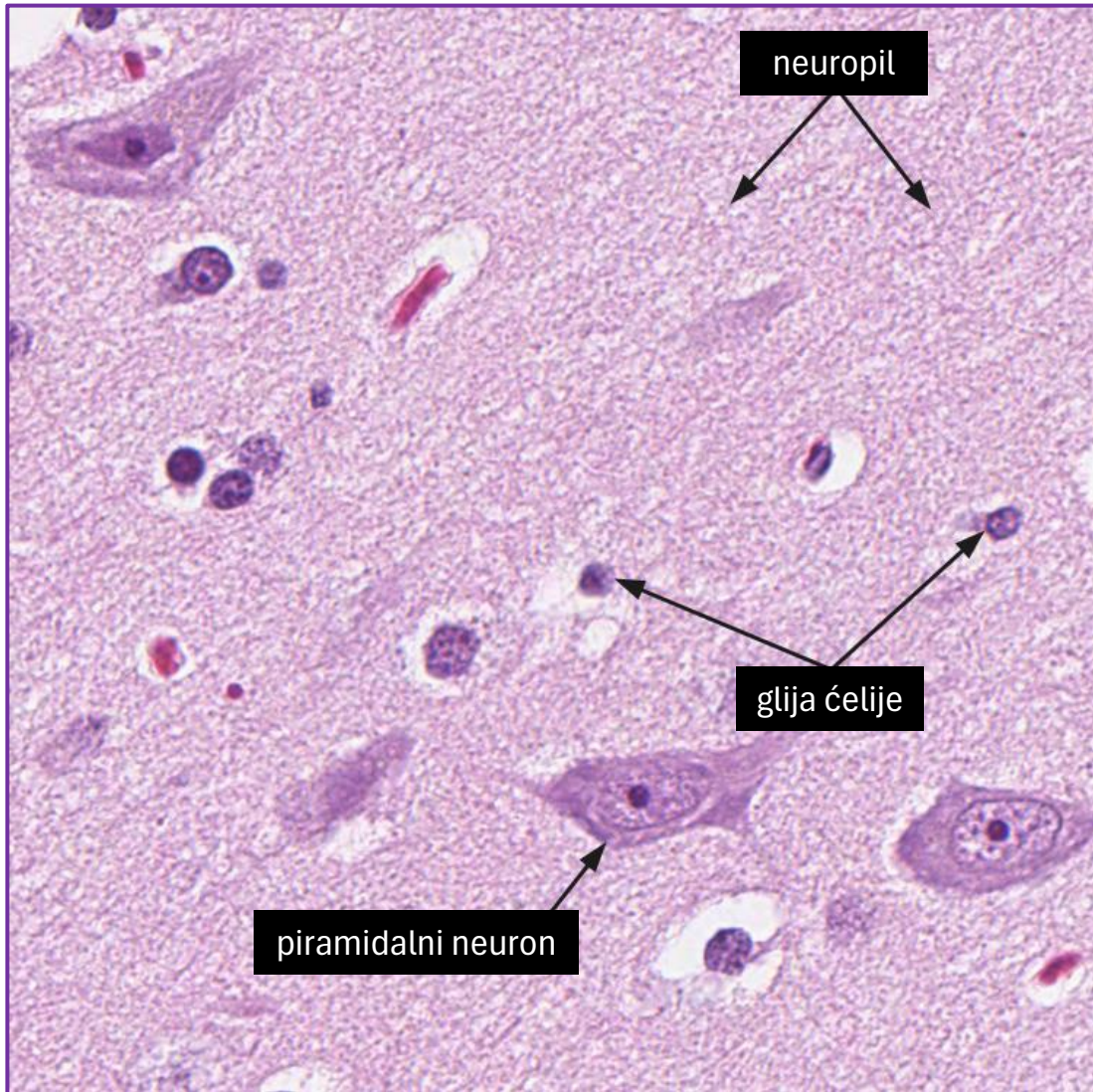
neuroni

neuroglia

neuropil

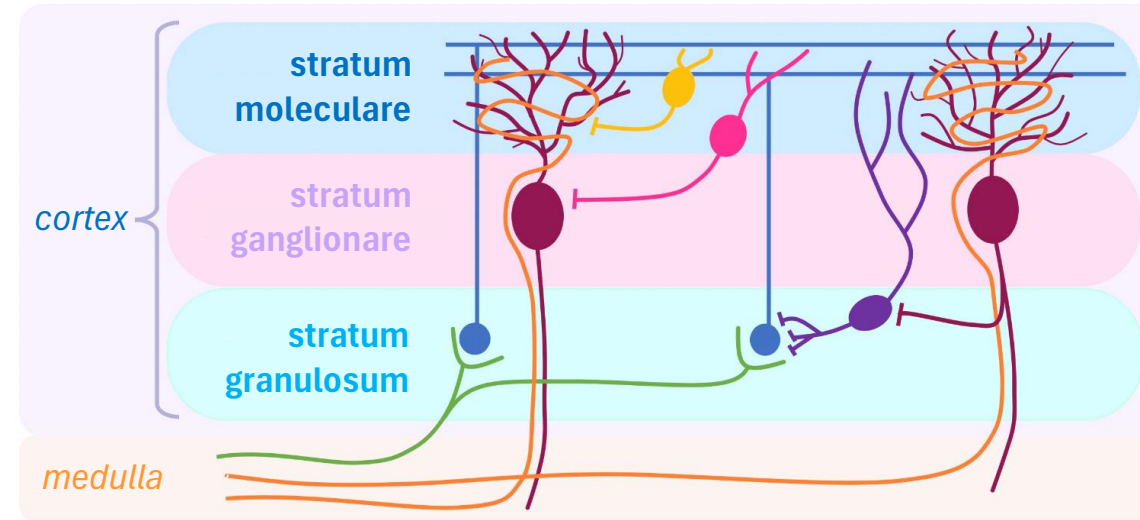
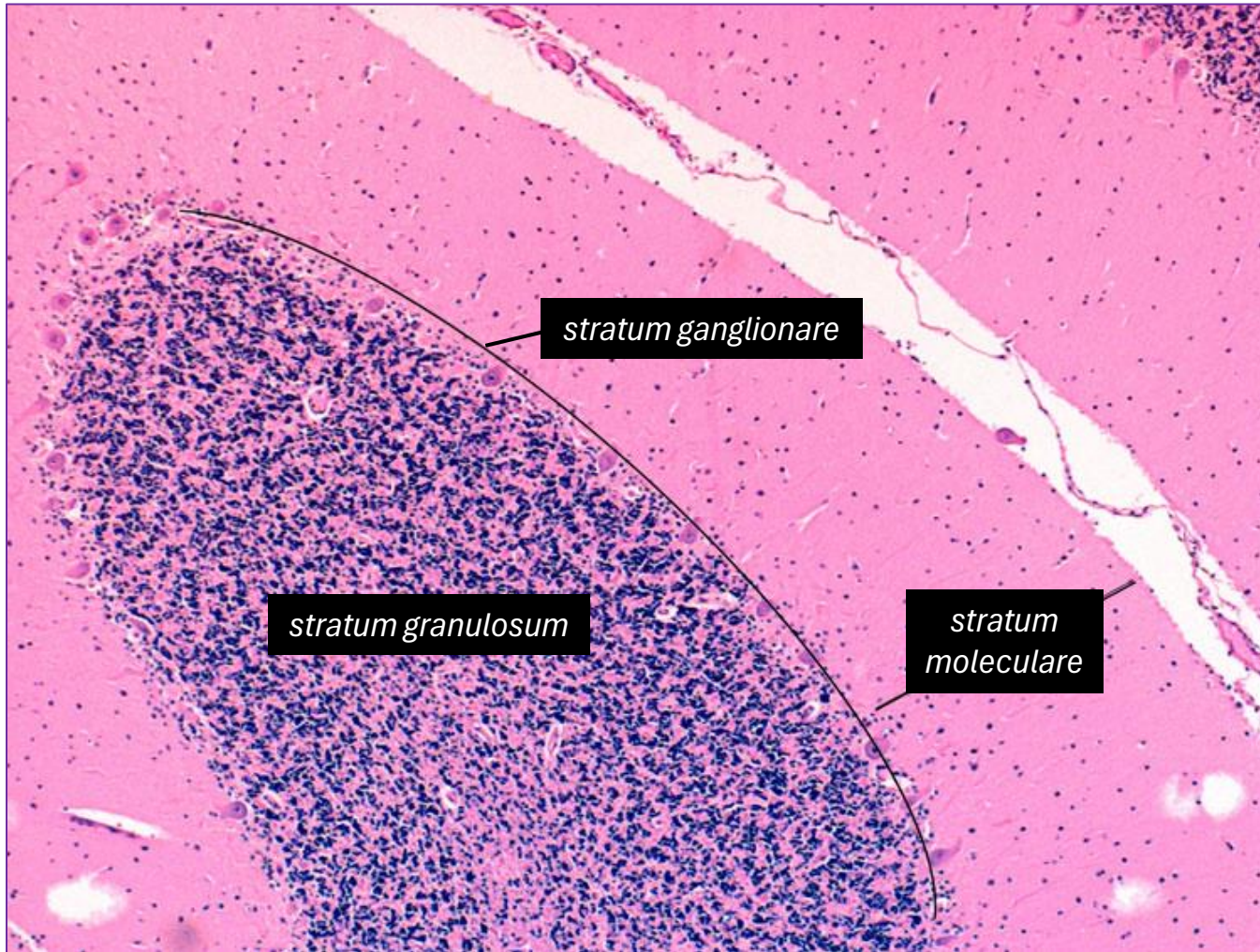


# Piramidalne i glija ćelije u kori velikog mozga



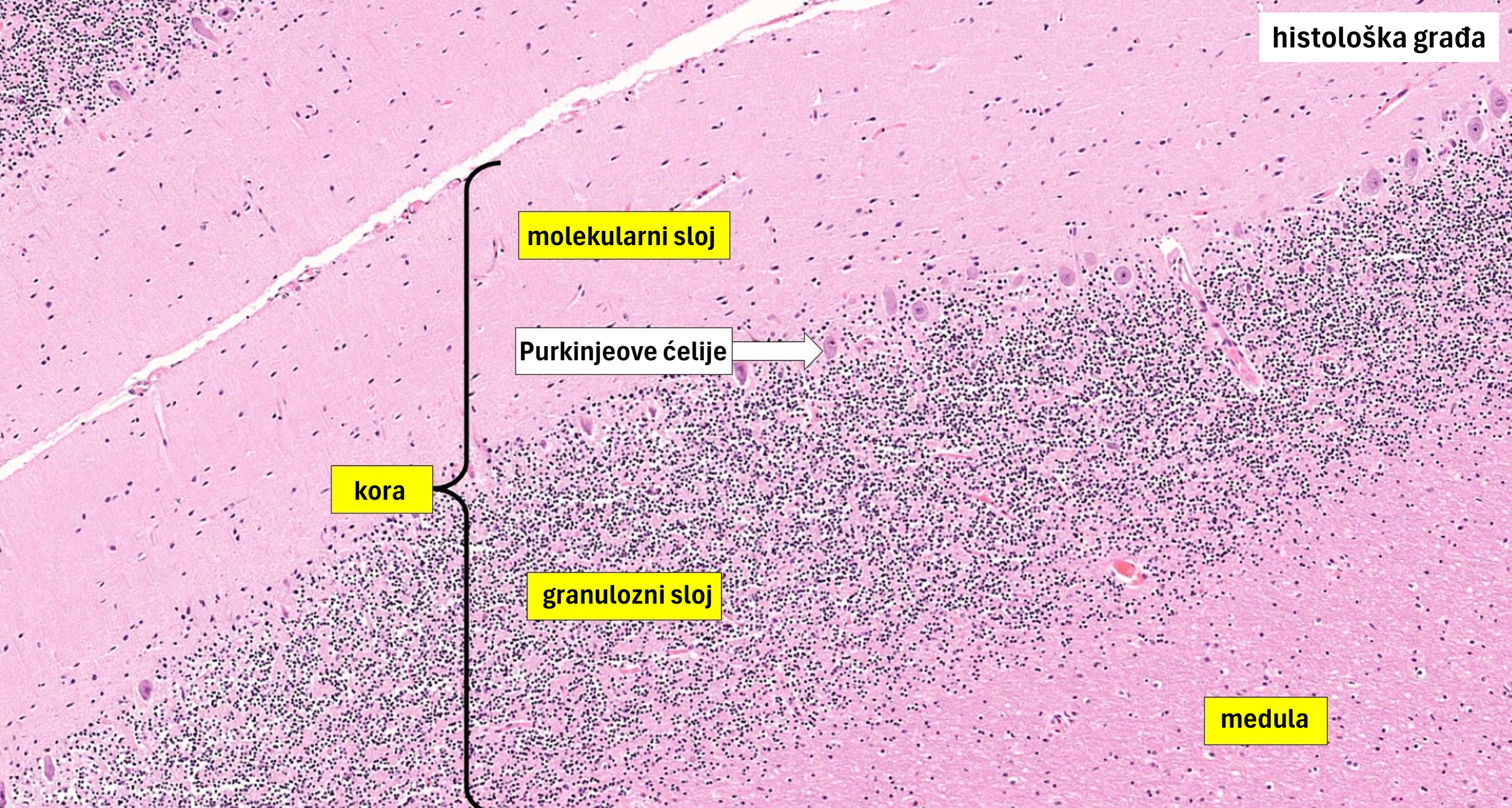


## 2) Nervno tkivo kore malog mozga



**mali mozak**  
(*cerebellum*)





molekularni sloj

Purkinjeove ćelije

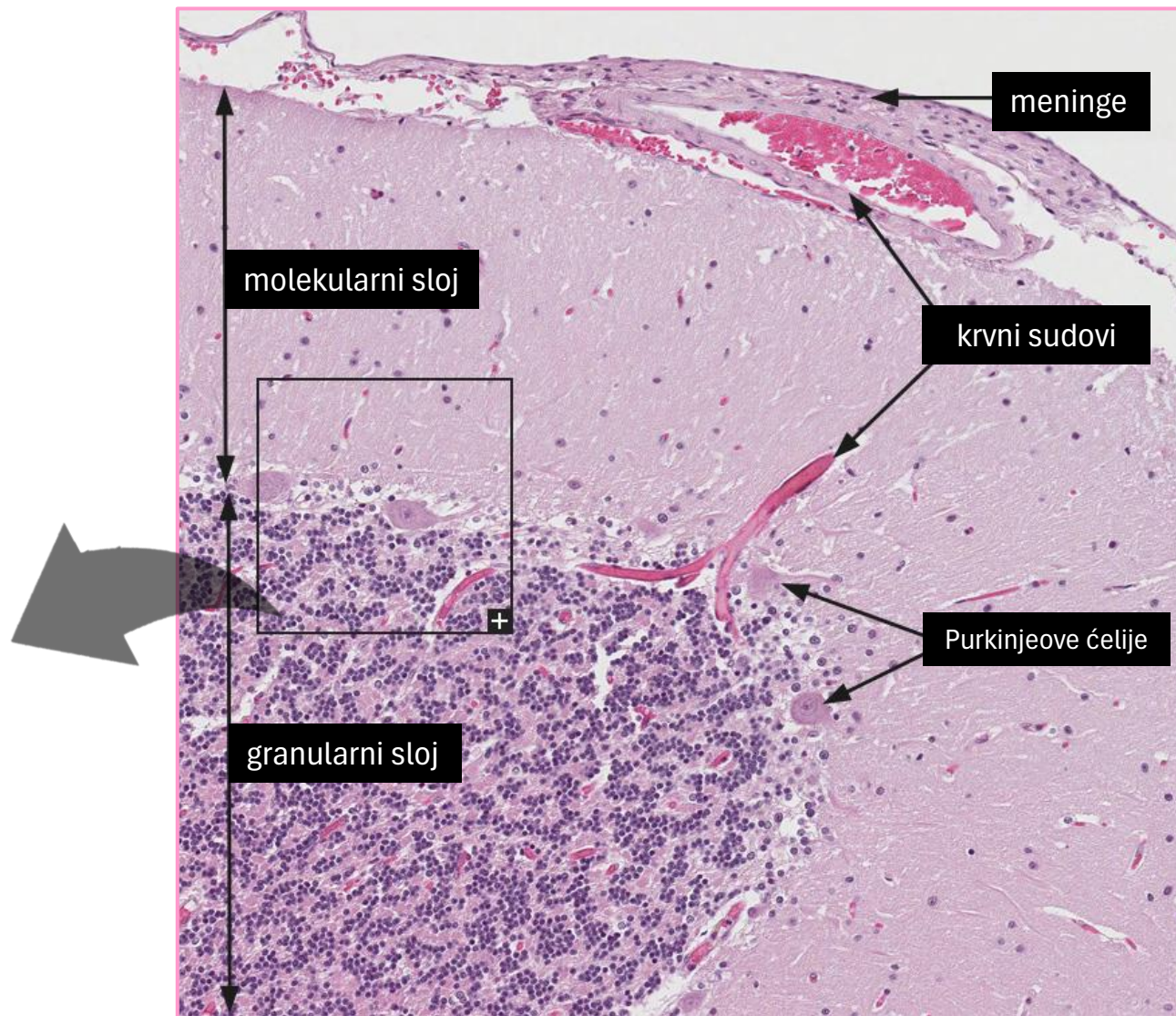
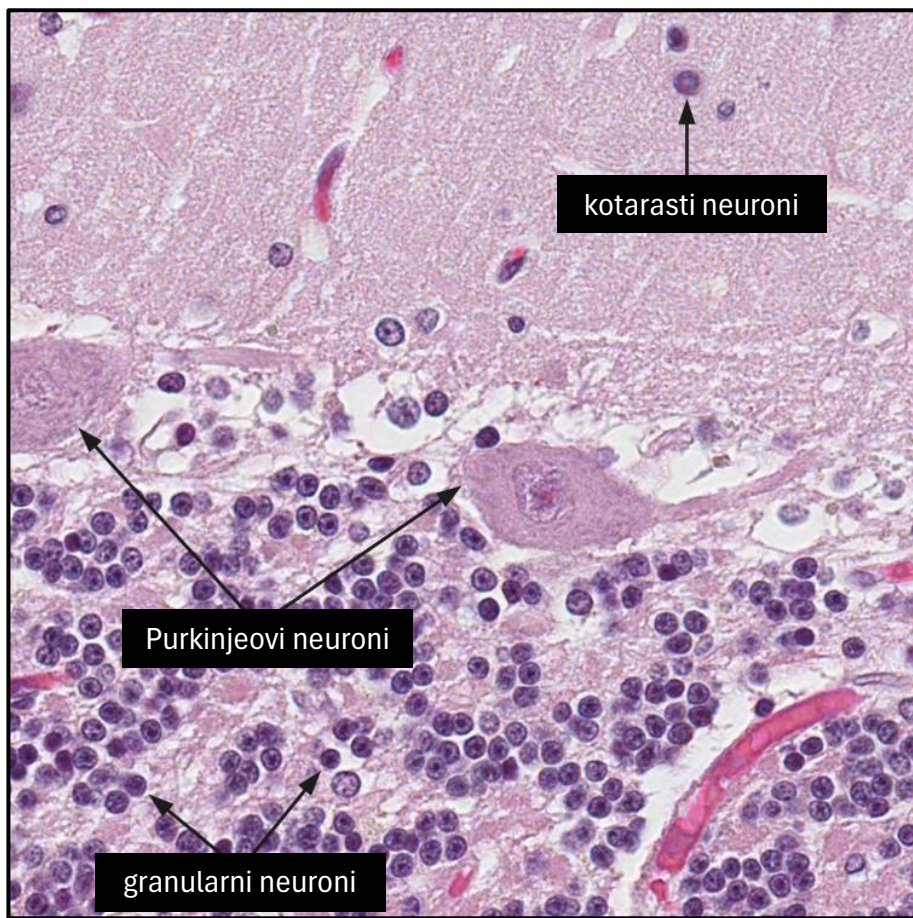
kora

granulozni sloj

medula

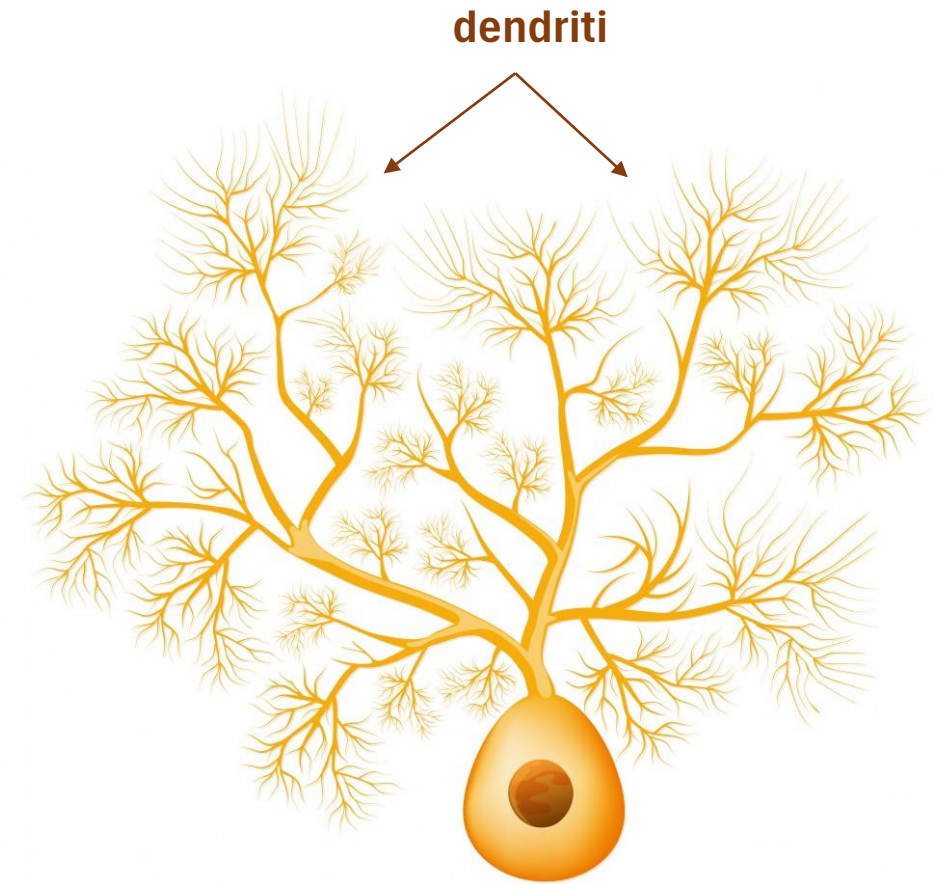
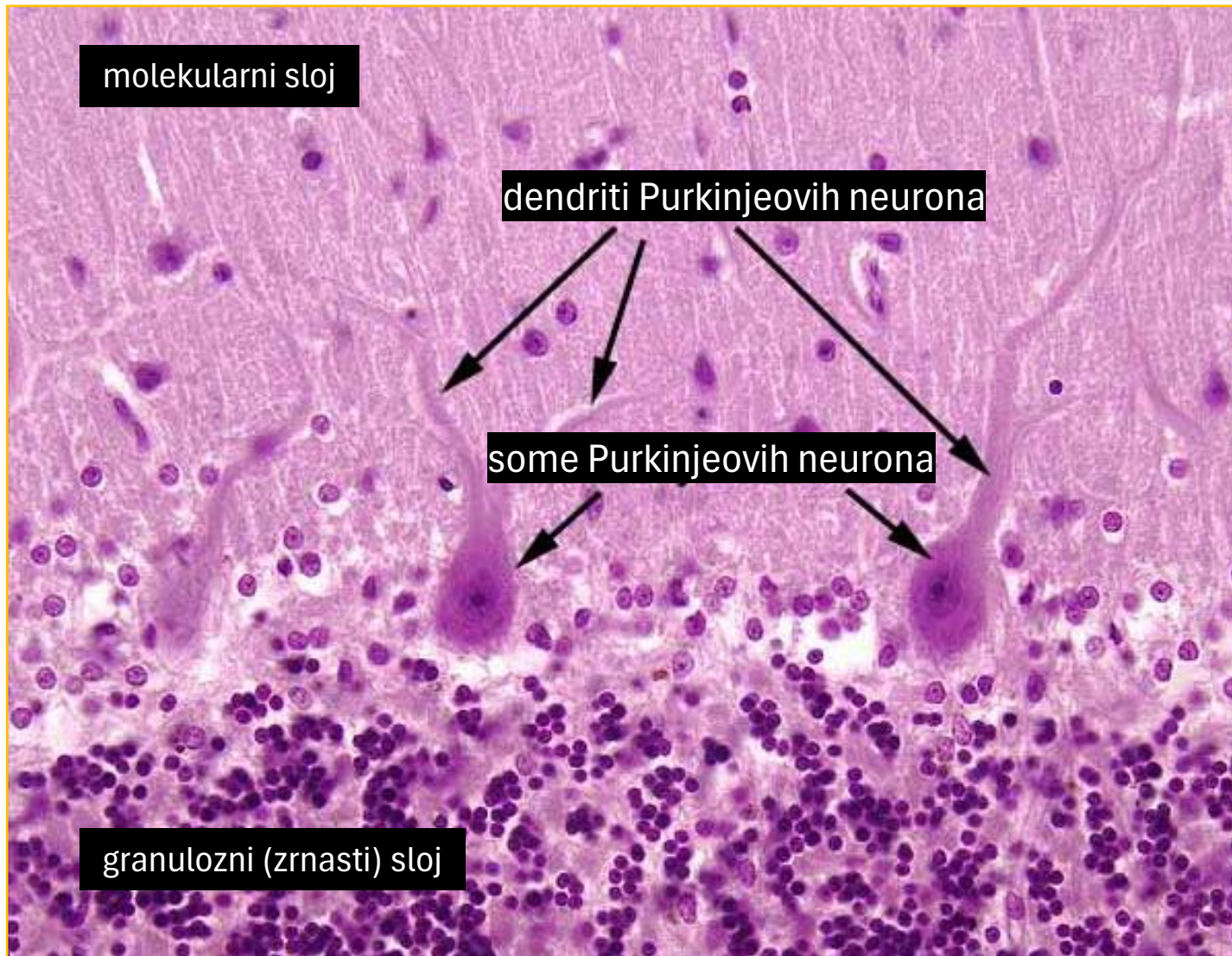


# Različiti oblici neurona u sivoj masi malog mozga





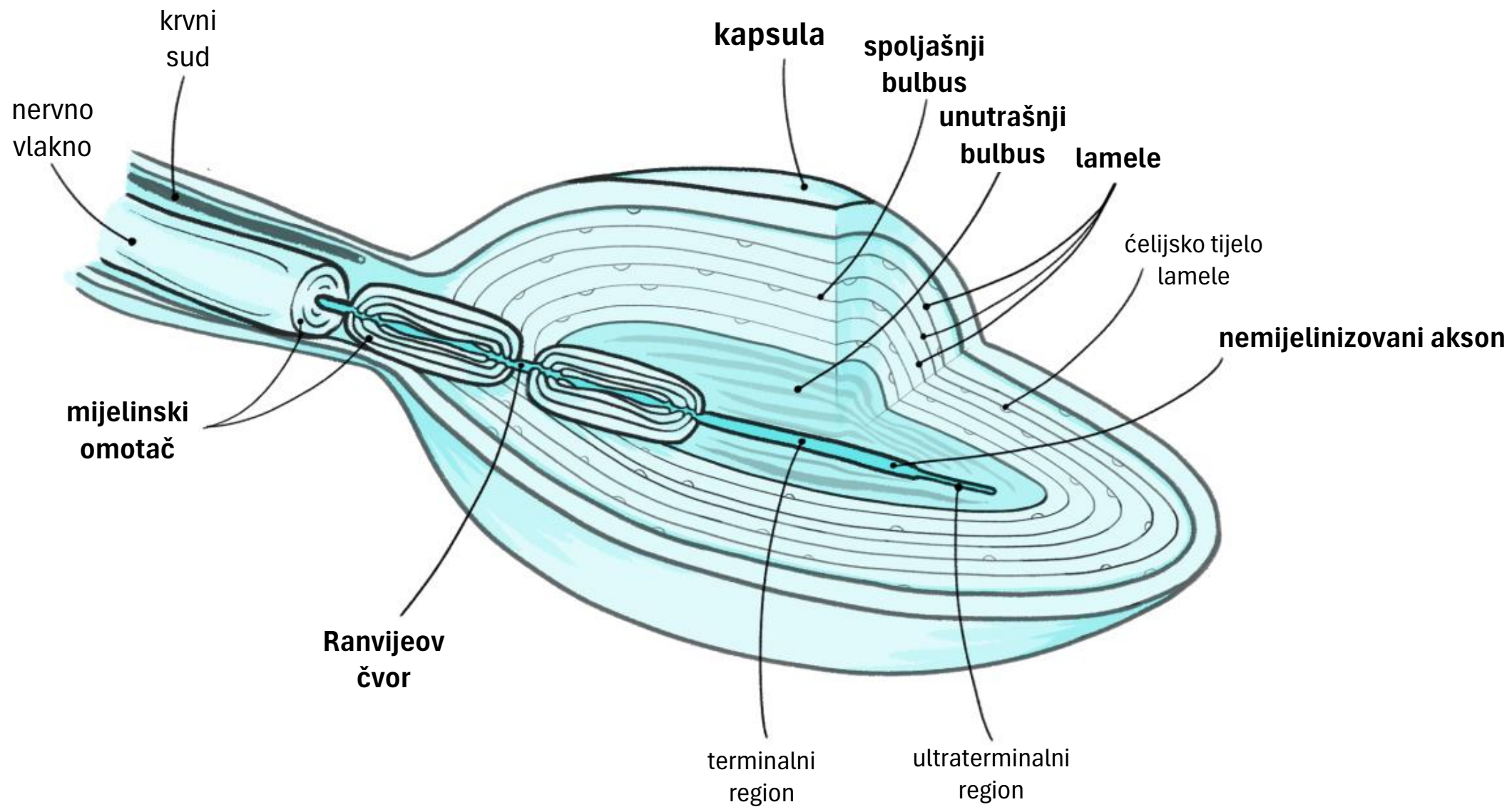
# Purkinjeovi neuroni



kruškast oblik neurona  
(Purkinjeova ćelija)

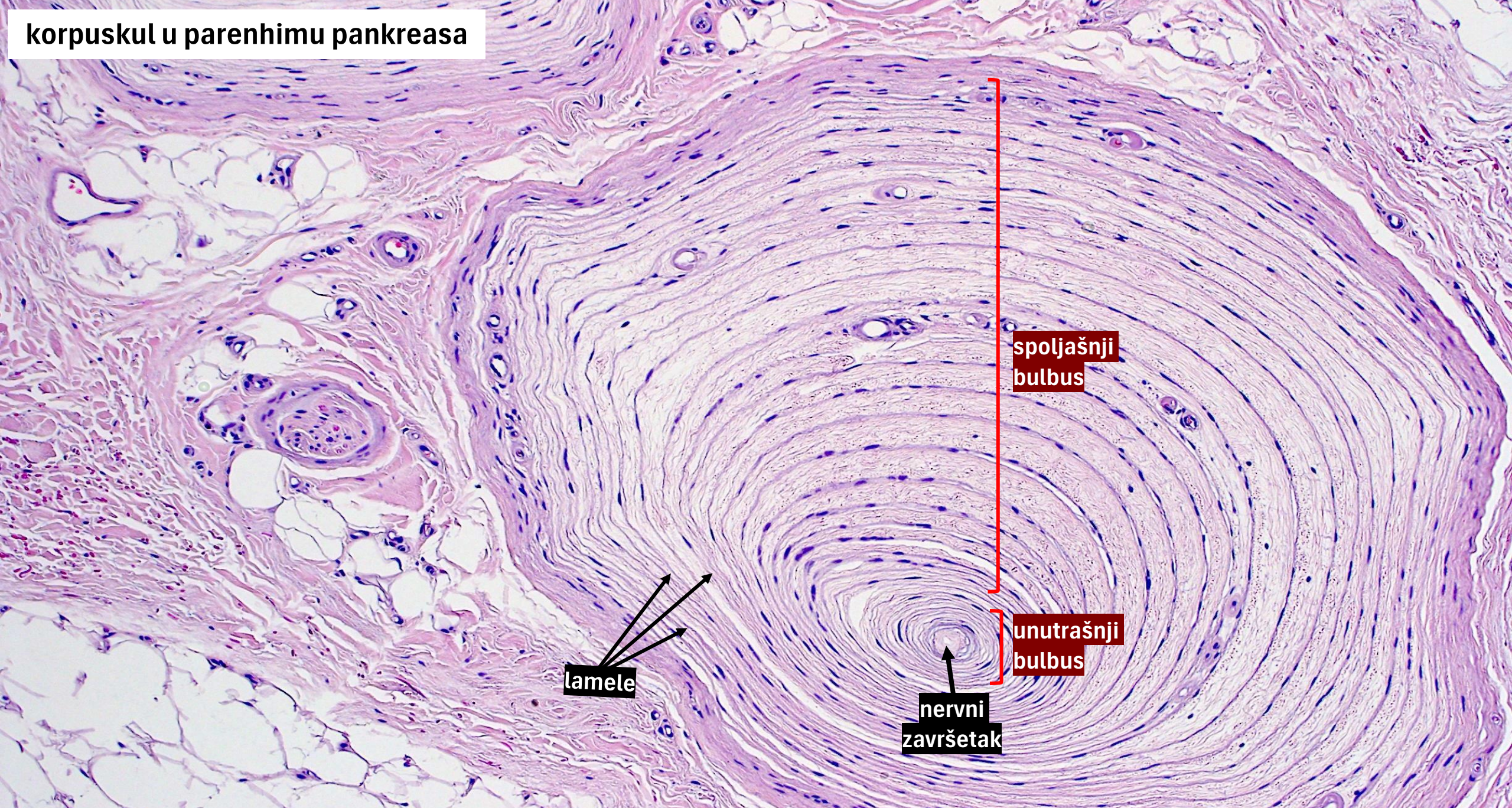


# 3) Fater-Pačinijev korpuskul





**korpuskul u parenhimu pankreasa**



**spoljašnji  
bulbus**

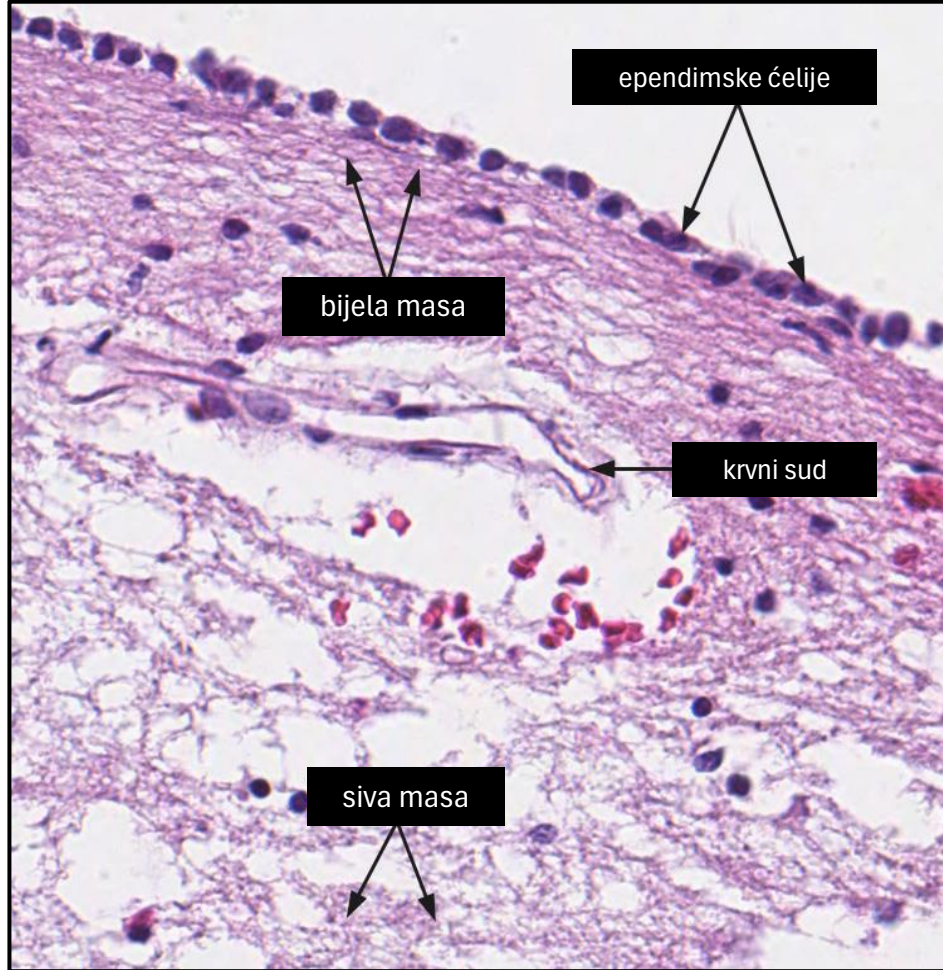
**unutrašnji  
bulbus**

**lamelle**

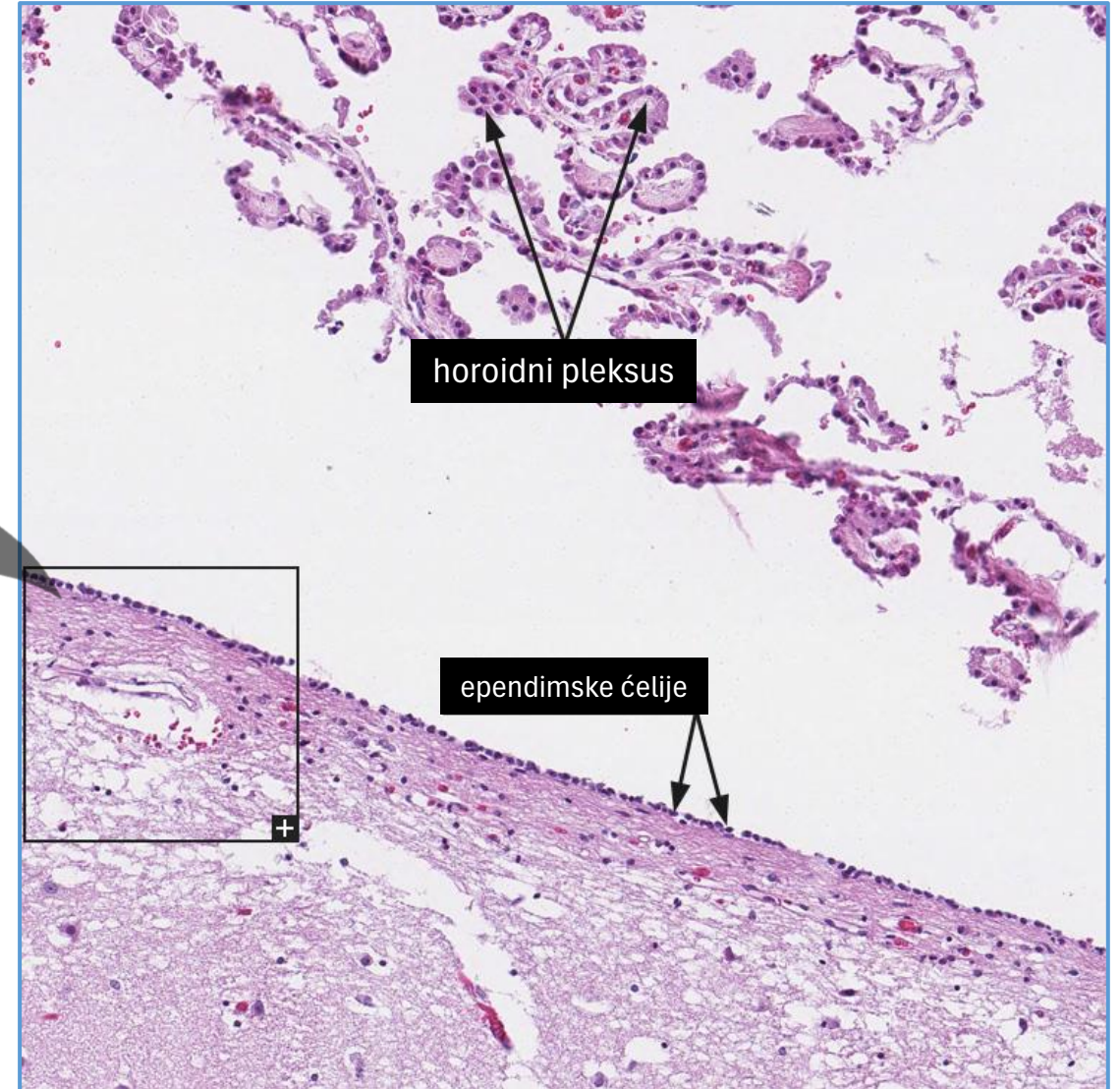
**nervni  
završetak**



# 4) Ependimske ćelije ventrikularnog sistema mozga



**bočna komora**  
(*ventriculus lateralis*)





# Ependimociti

