

11V: Mišićno tkivo

PREPARATI:

- 1) Poprečno-prugasto mišićno tkivo
- 2) Srčano mišićno tkivo
- 3) Glatko mišićno tkivo

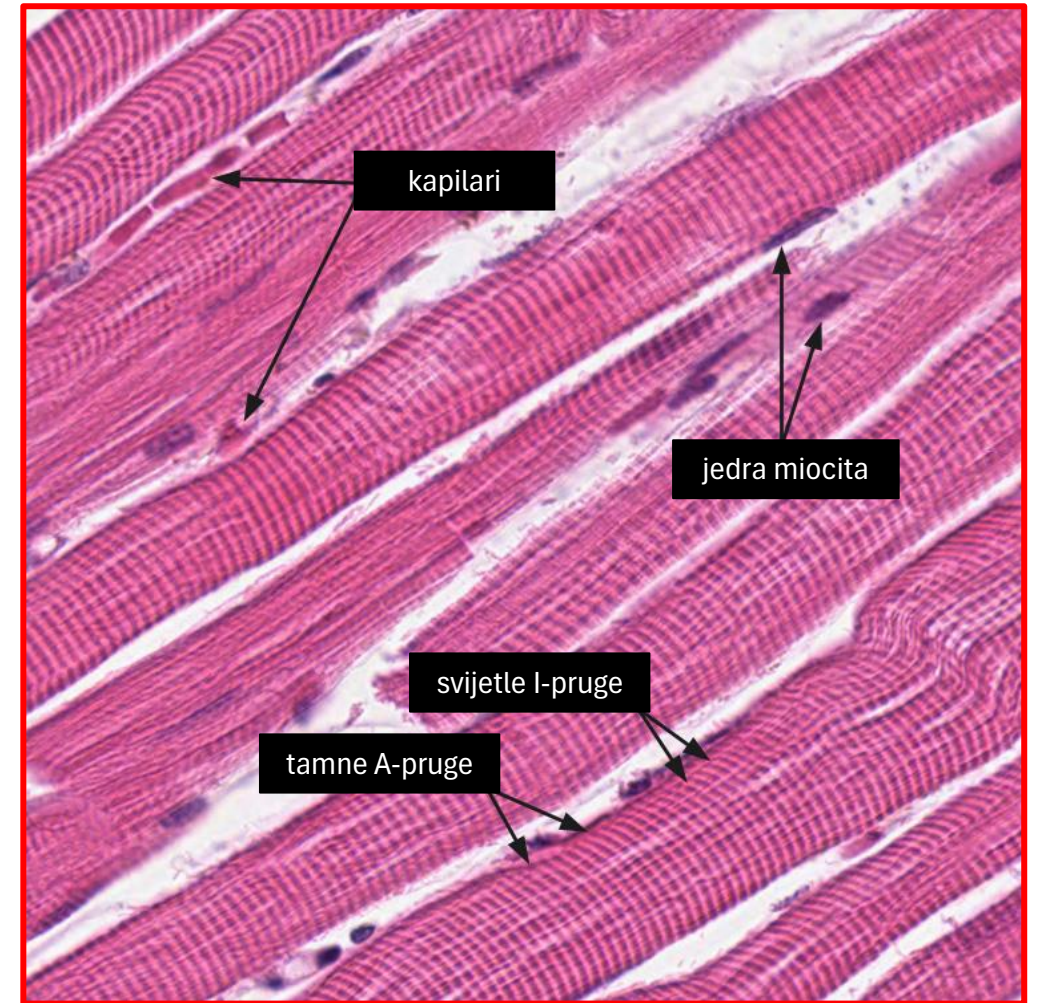
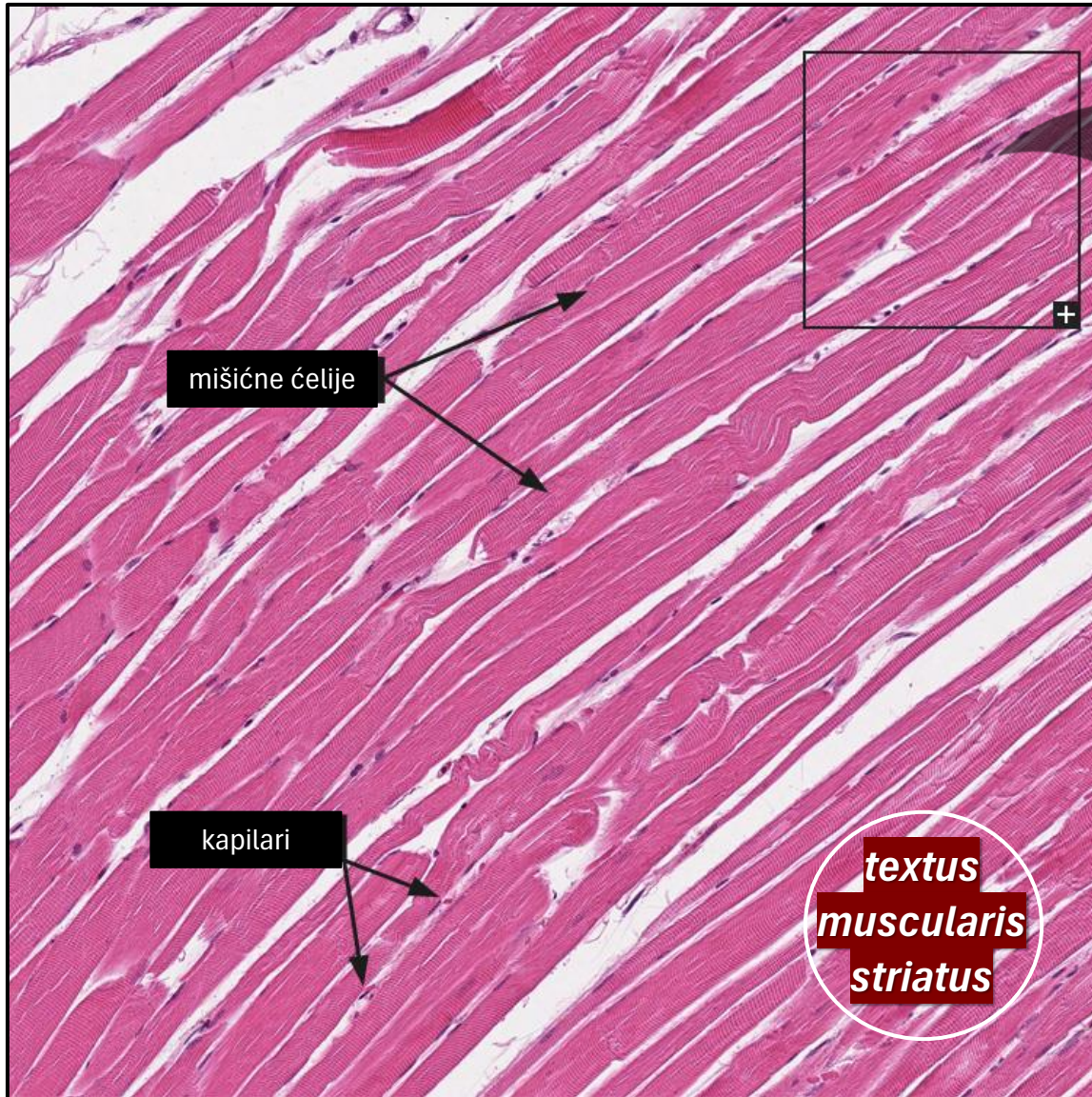
Mijat Božović

CITOLOGIJA I TKIVA

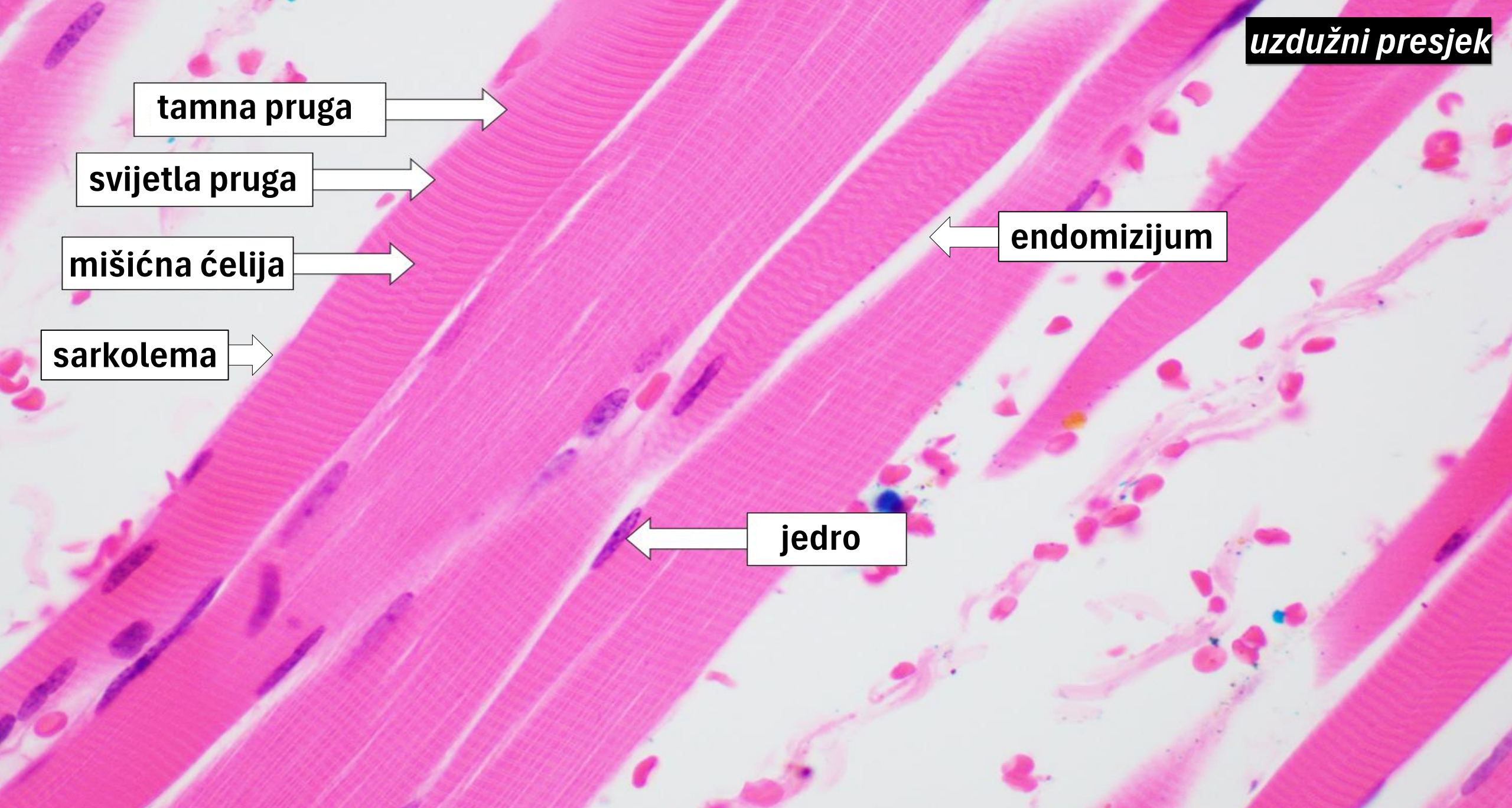
materijal za laboratorijske vježbe



1) Poprečno-prugasto mišično tkivo



uzdužni presjek



tamna pruga




svijetla pruga



mišićna ćelija



sarkolema




endomizijum



jedro

poprečni presjek

mišićna ćelija



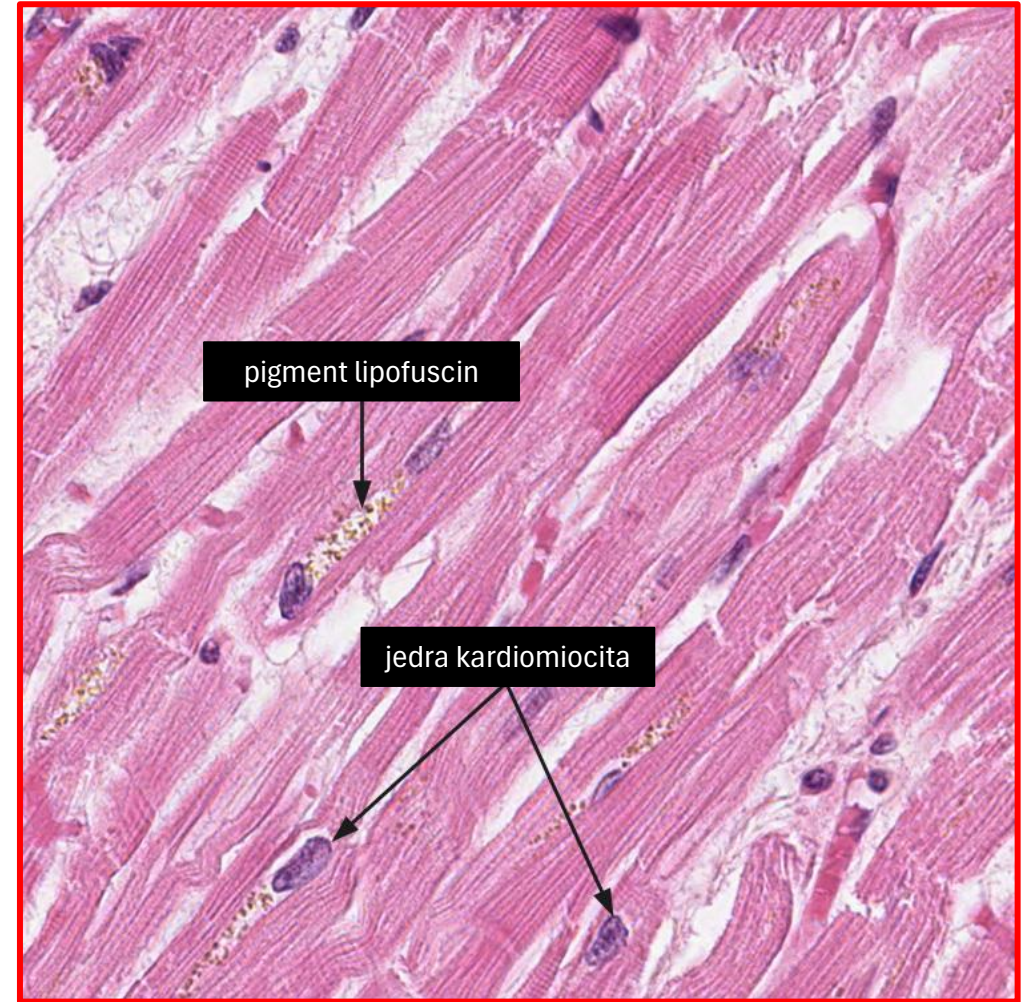
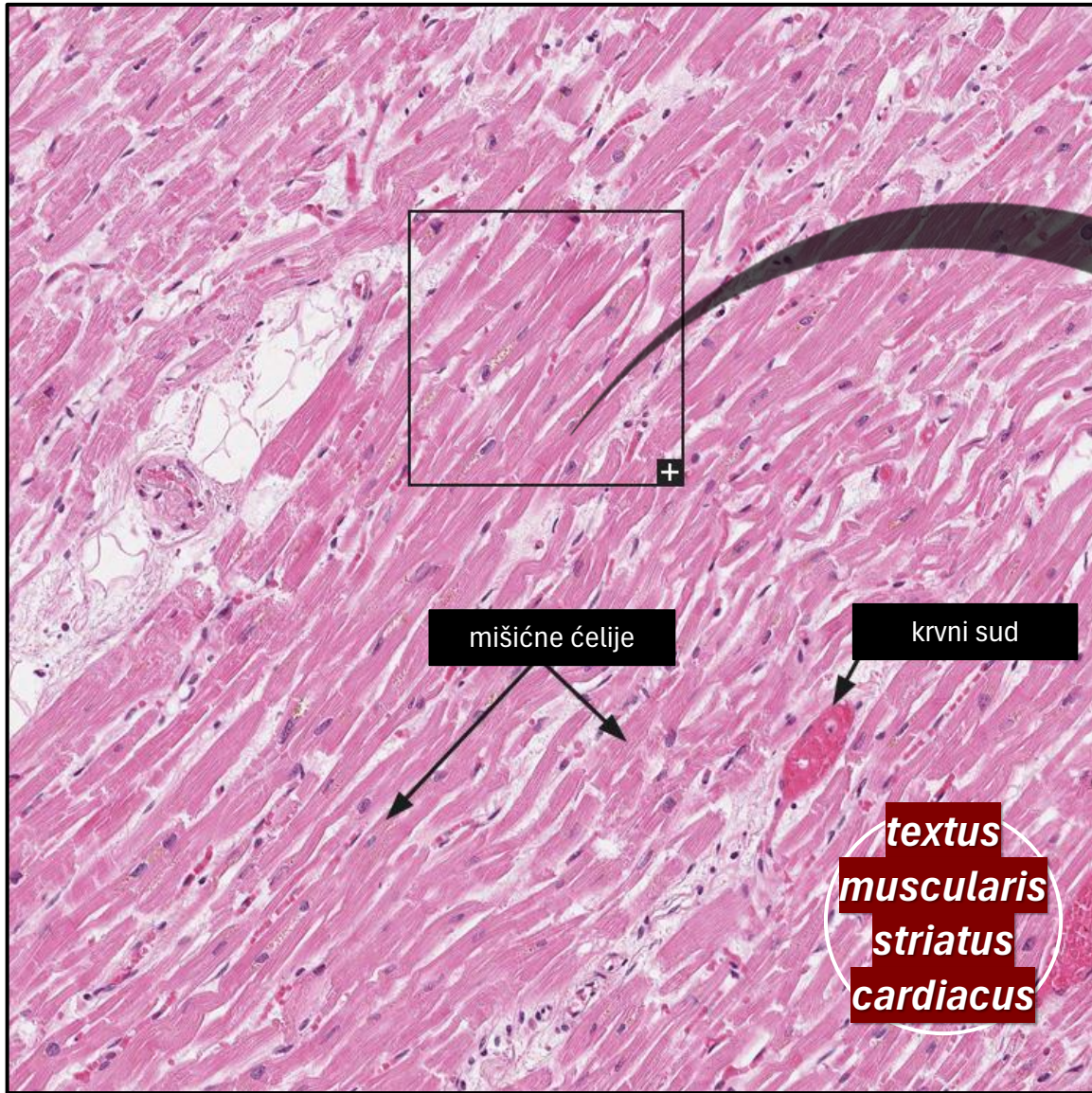
jedro

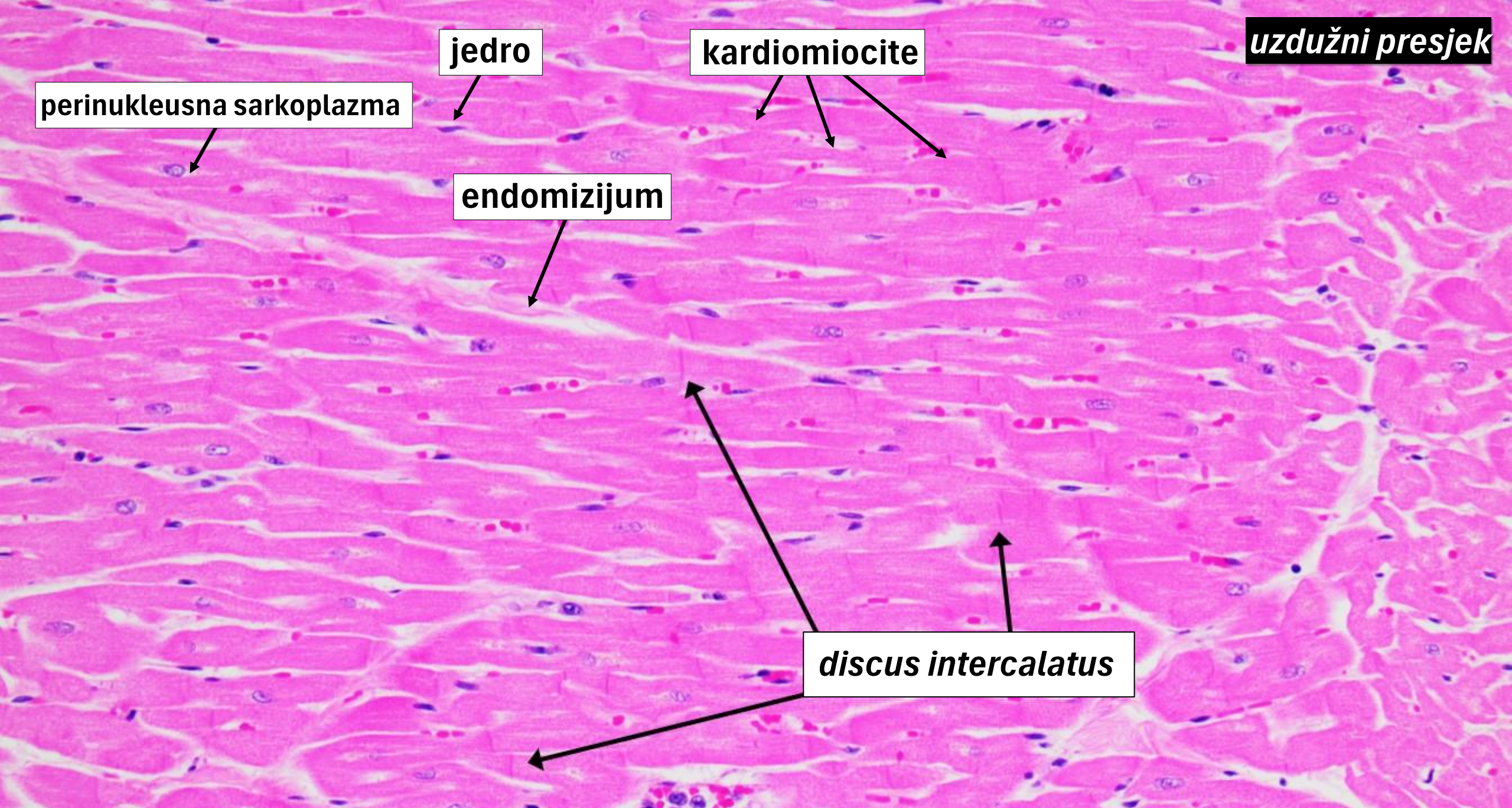


endomizijum



2) Srčano mišićno tkivo





uzdužni presjek

jedro

kardiomiocyte

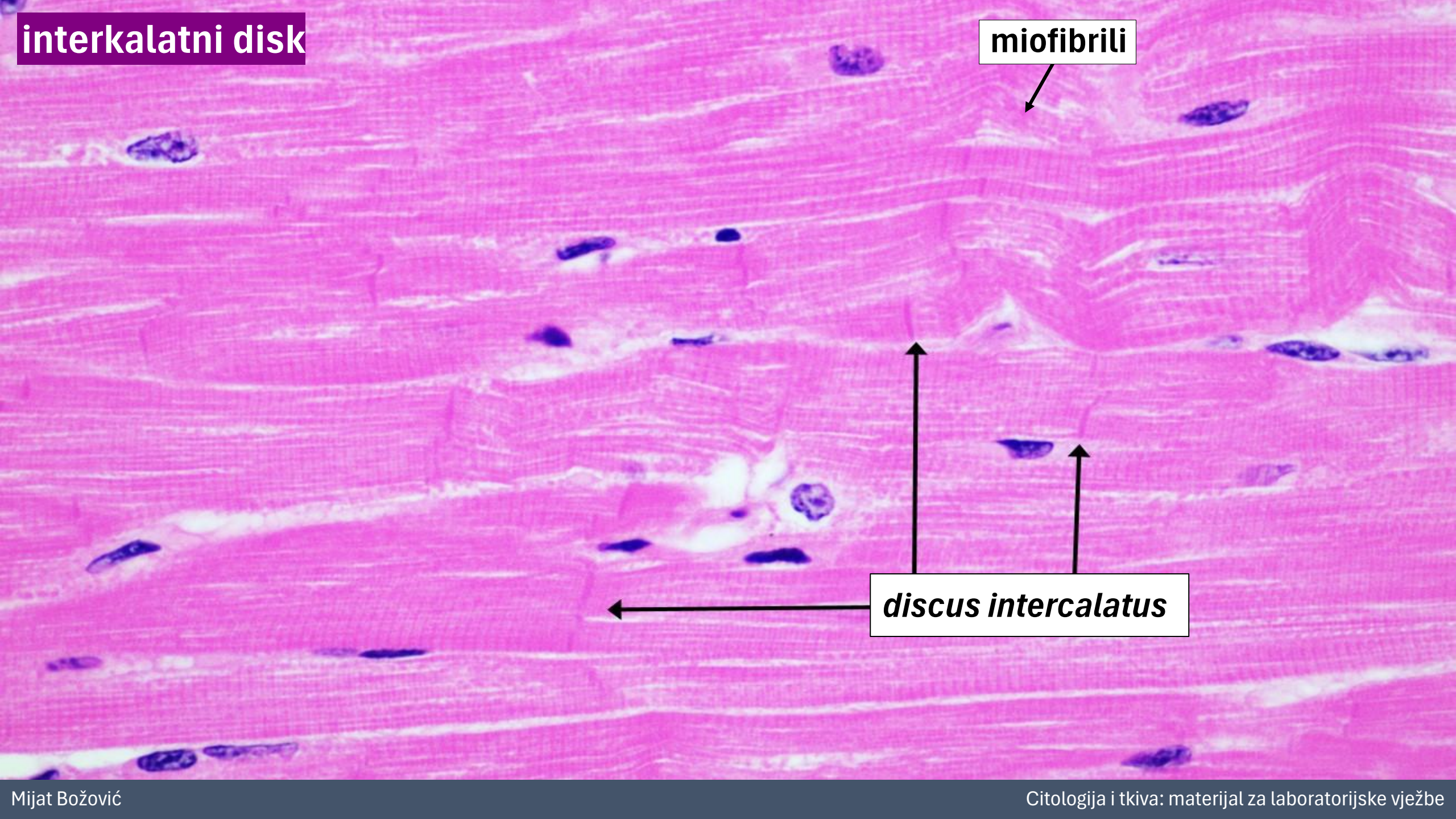
perinukleusna sarkoplazma

endomizijum

discus intercalatus

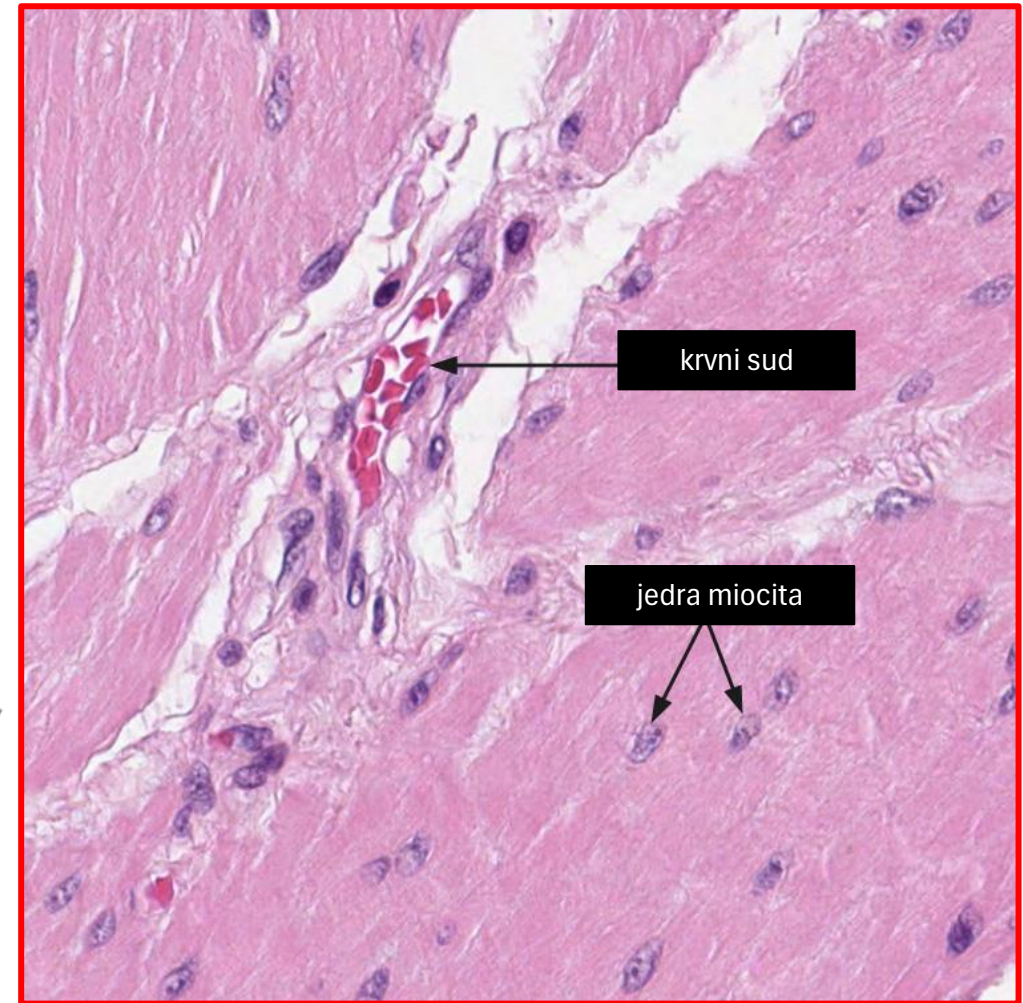
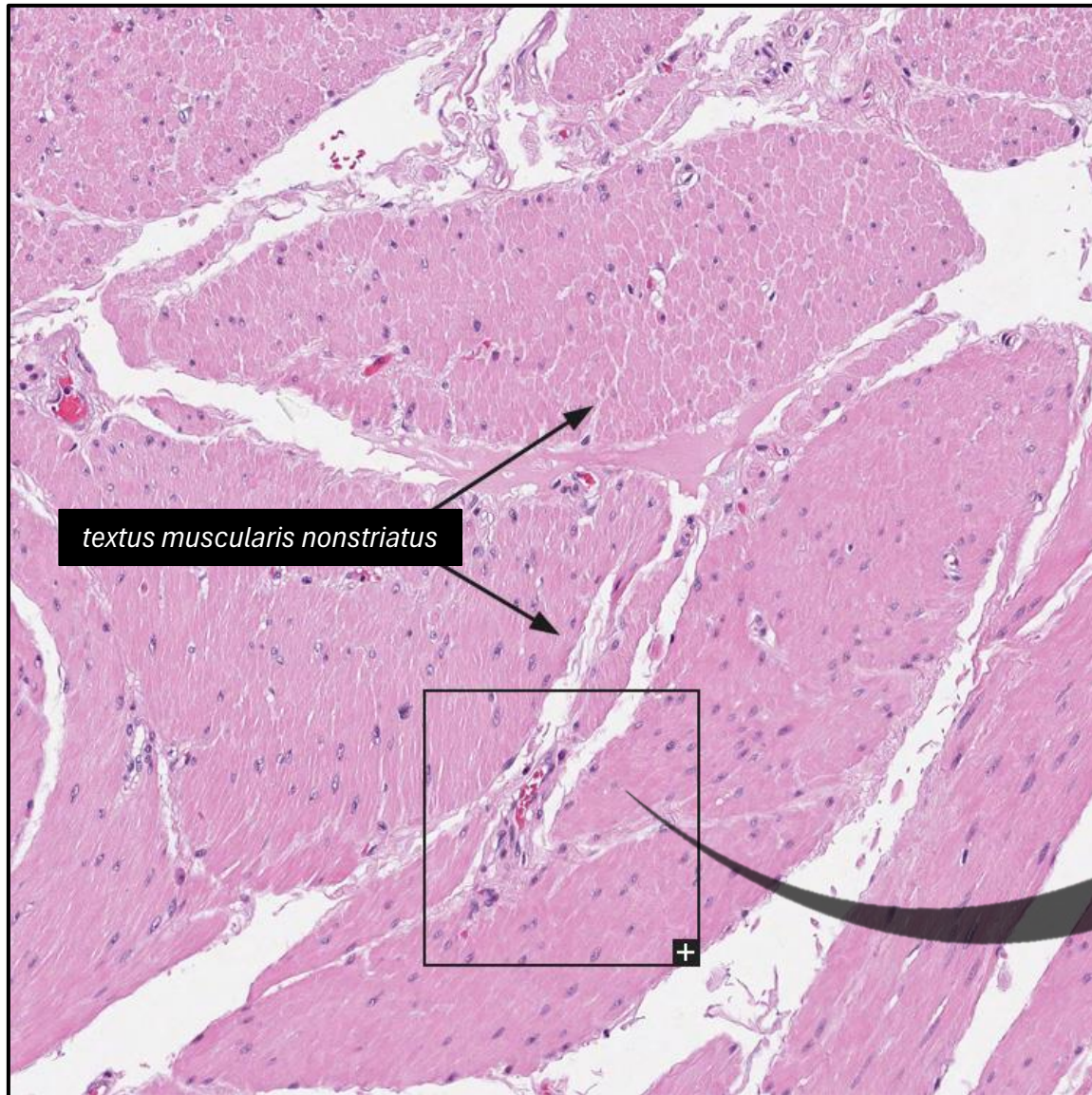
interkalatni disk

miofibrili



discus intercalatus

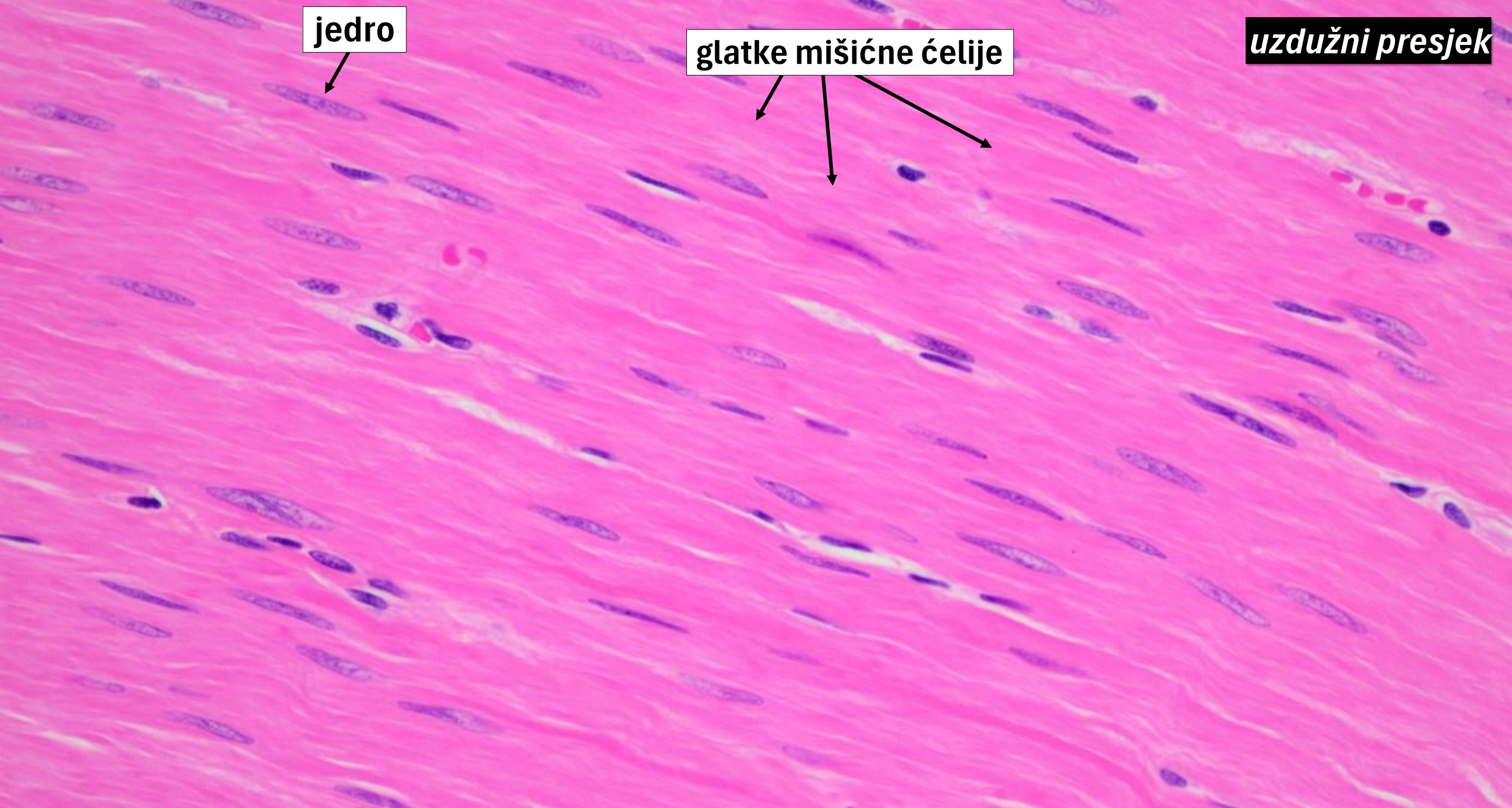
3) Glatko mišićno tkivo

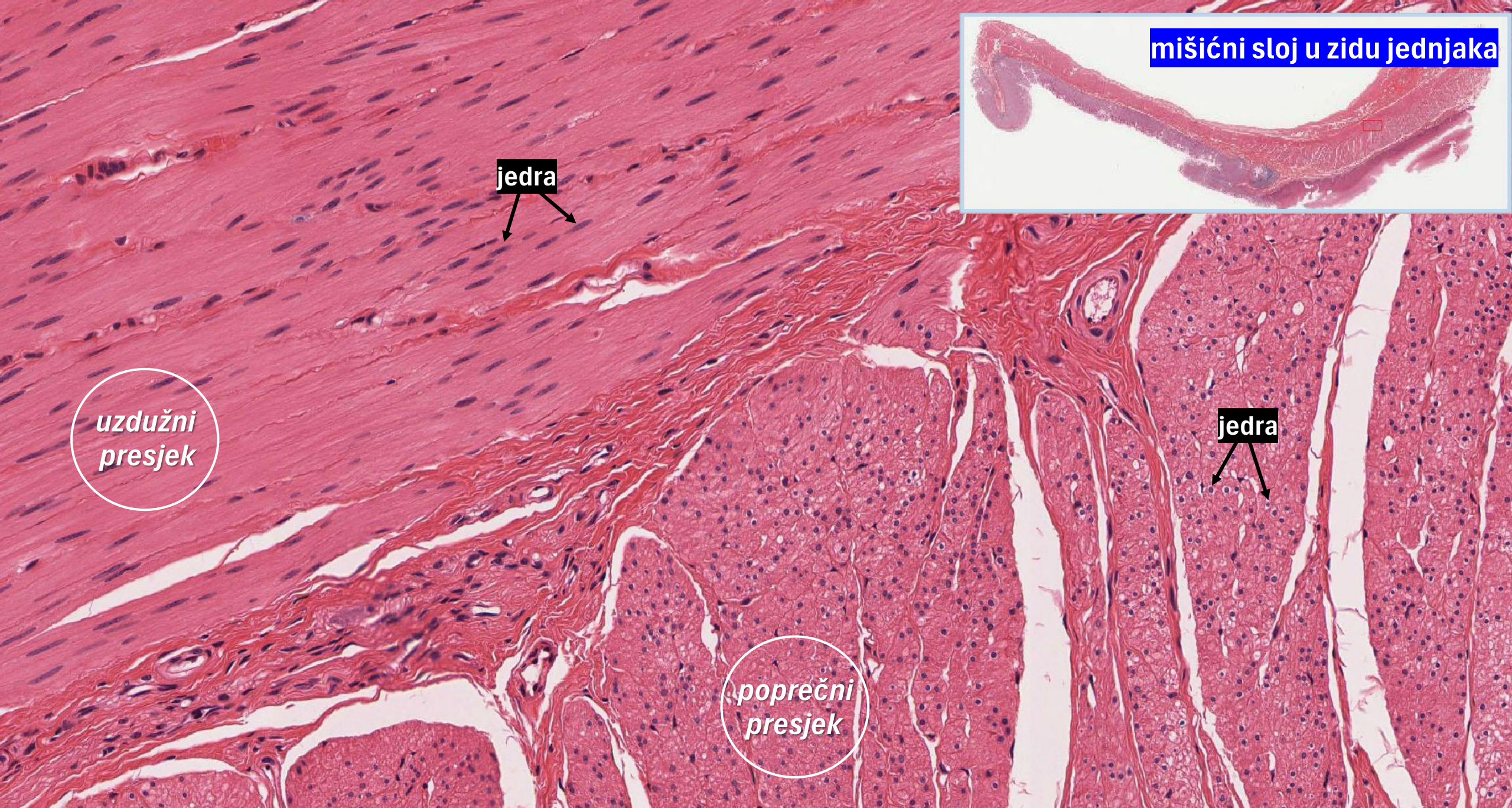


jedro

glatke mišićne ćelije

uzdužni presjek





mišićni sloj u zidu jednjaka

jedra

uzdužni
presjek

poprečni
presjek

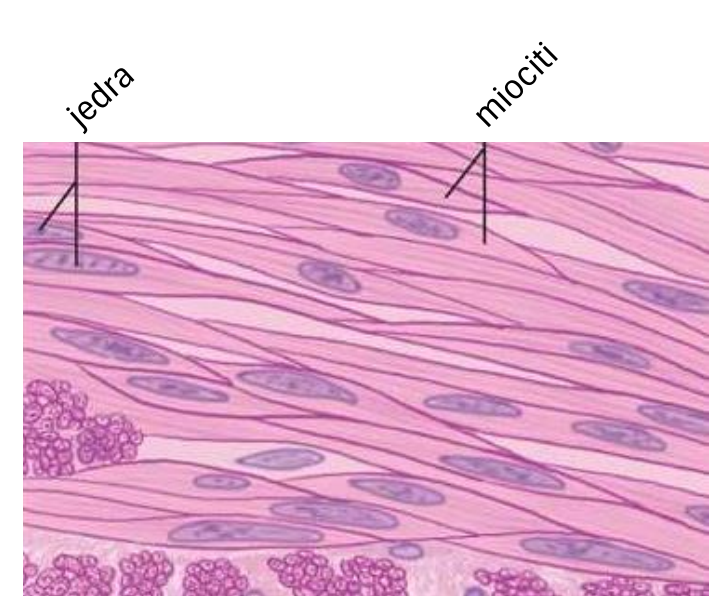
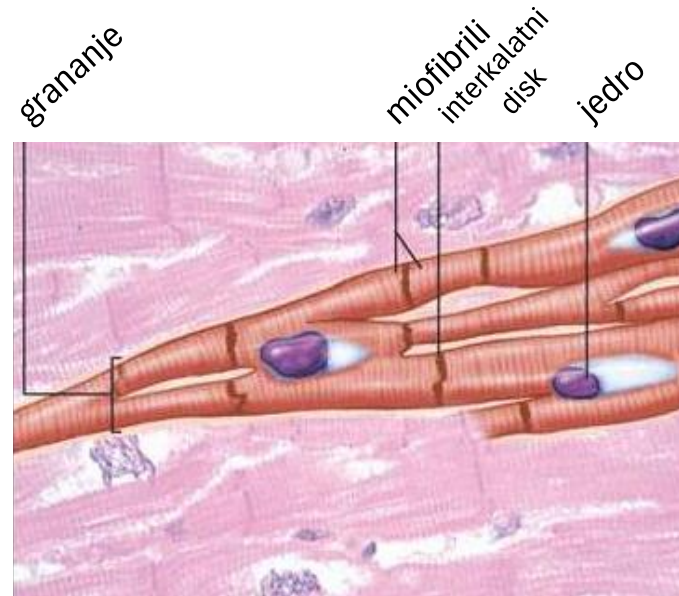
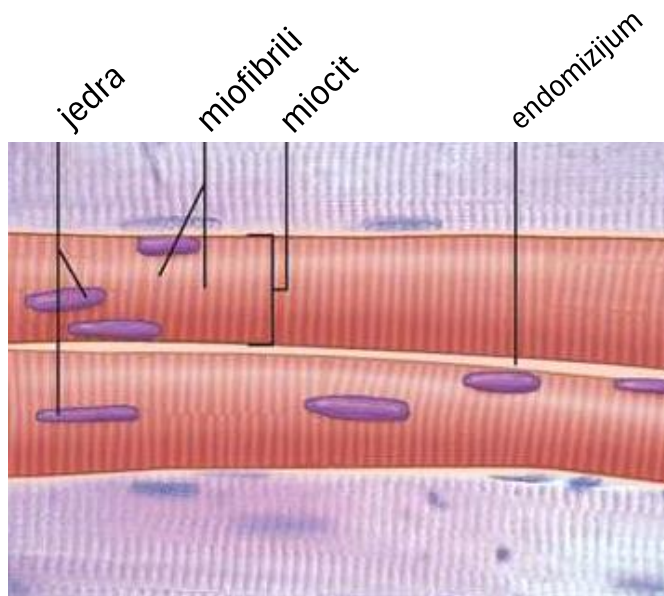
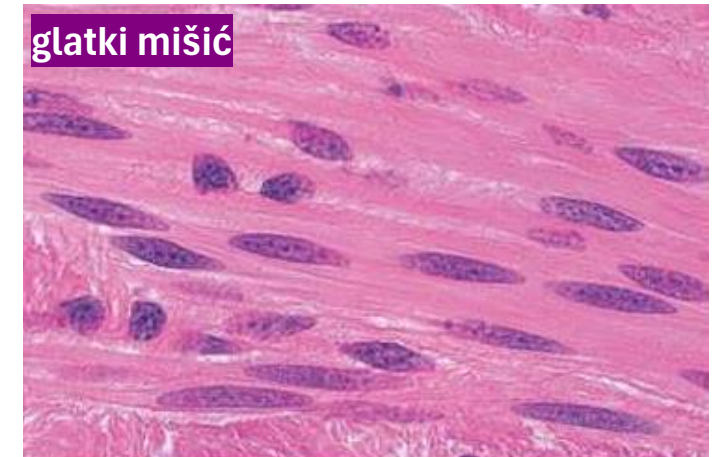
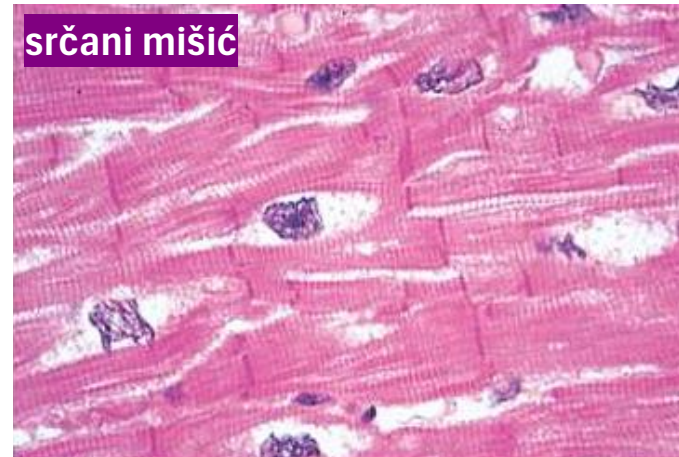
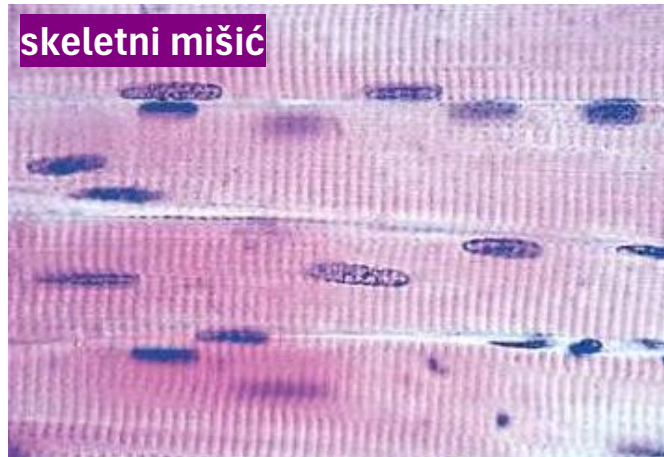
jedra

DODATAK:

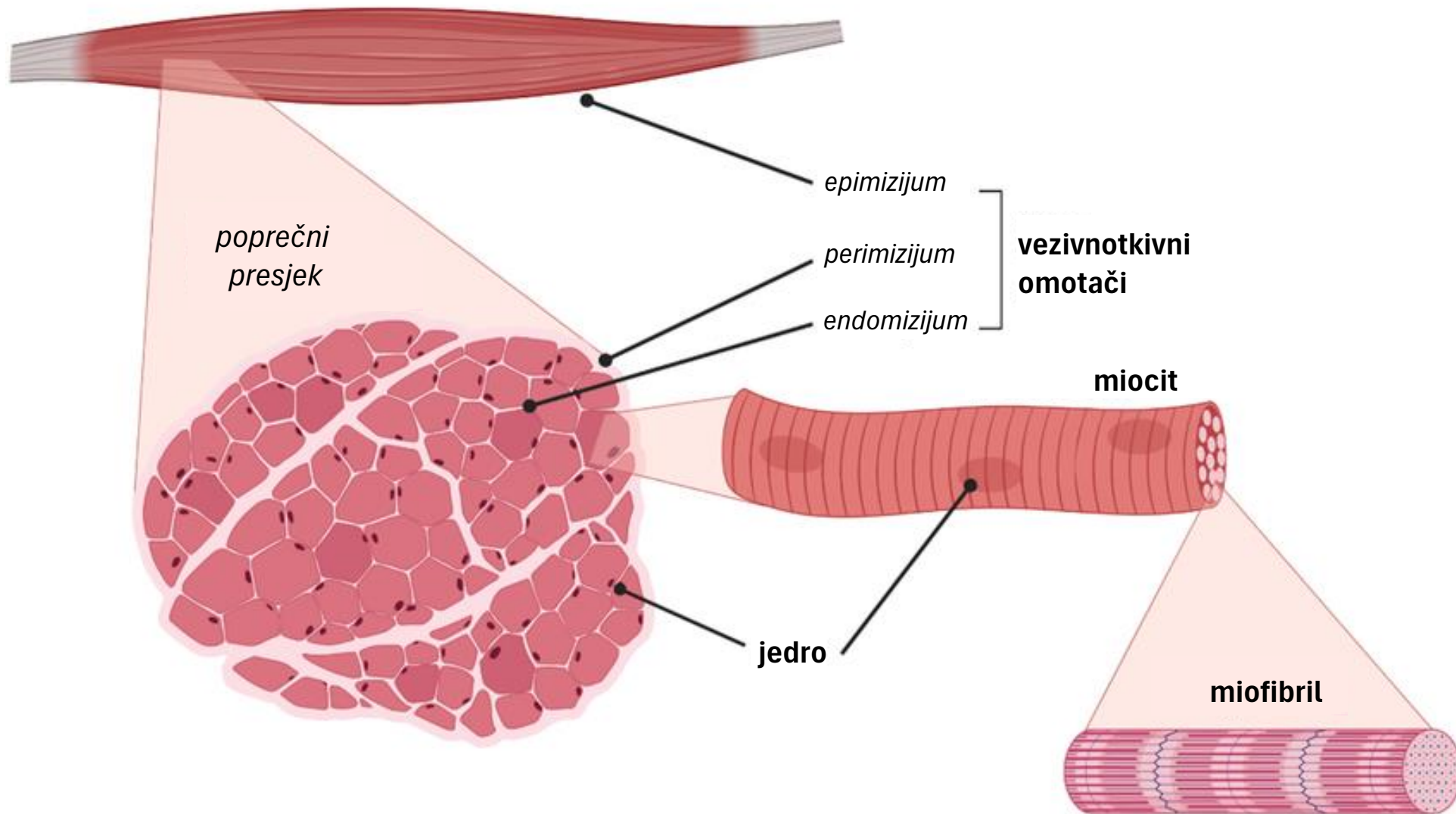
šeme sa histološkim preparatima:

- A) Tipovi mišićnog tkiva**
- B) Organizacija poprečno-prugastog mišićnog tkiva**
- C) Interkalatni diskovi u srčanom mišićnom tkivu**
- D) Glatko mišićno tkivo**

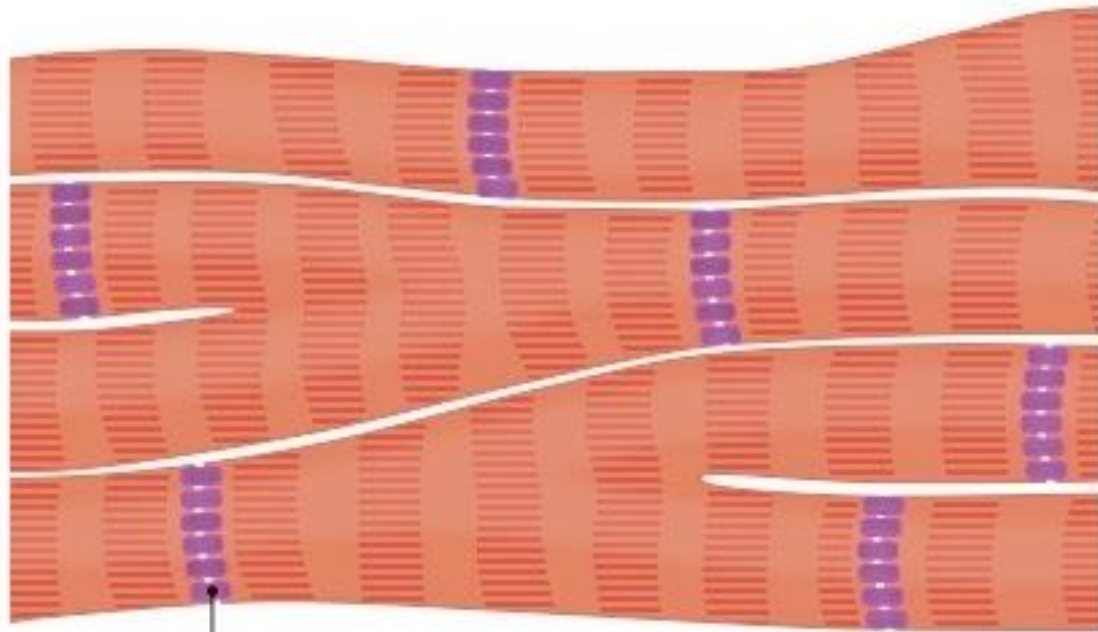
A) Tipovi mišićnog tkiva



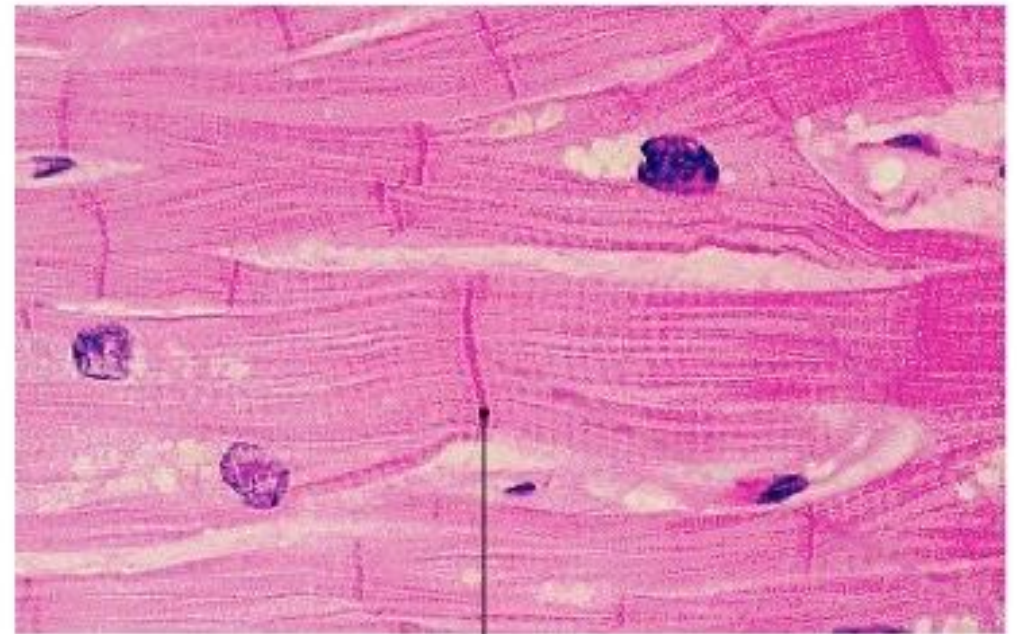
B) Organizacija poprečno-prugastog mišićnog tkiva



C) Interkalatni diskovi u srčanom mišićnom tkivu



discus intercalatus



discus intercalatus

D) Glatko mišićno tkivo

