

8V: Epitelna i vezivna tkiva

PREPARATI:

- 1) Hijalina hrskavica
- 2) Elastična hrskavica
- 3) Epitelno i vezivno tkivo u dušniku

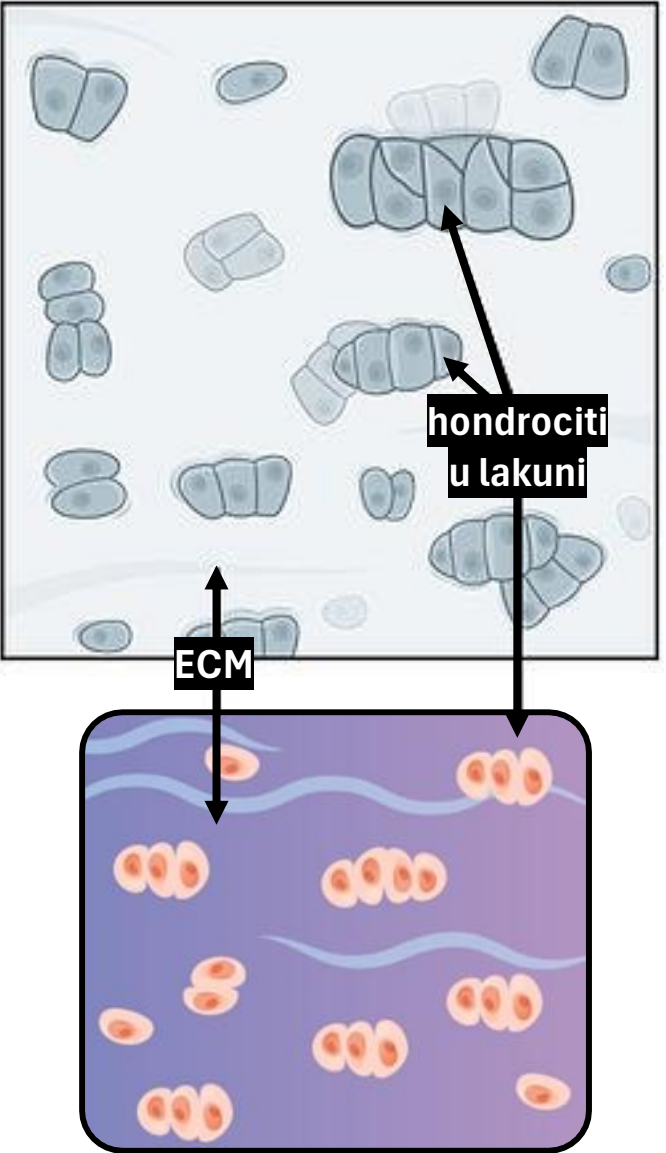
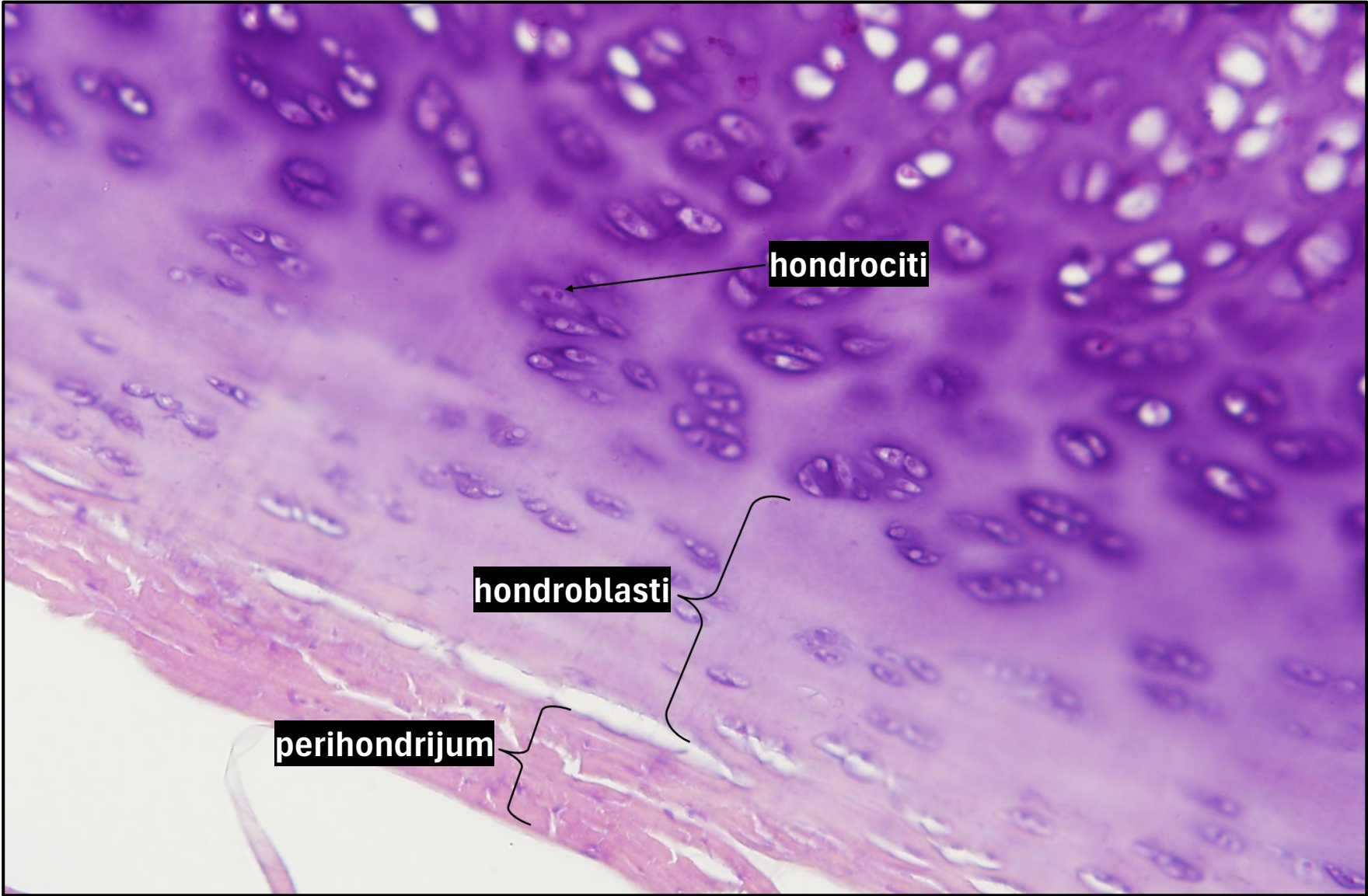
Mijat Božović

CITOLOGIJA I TKIVA

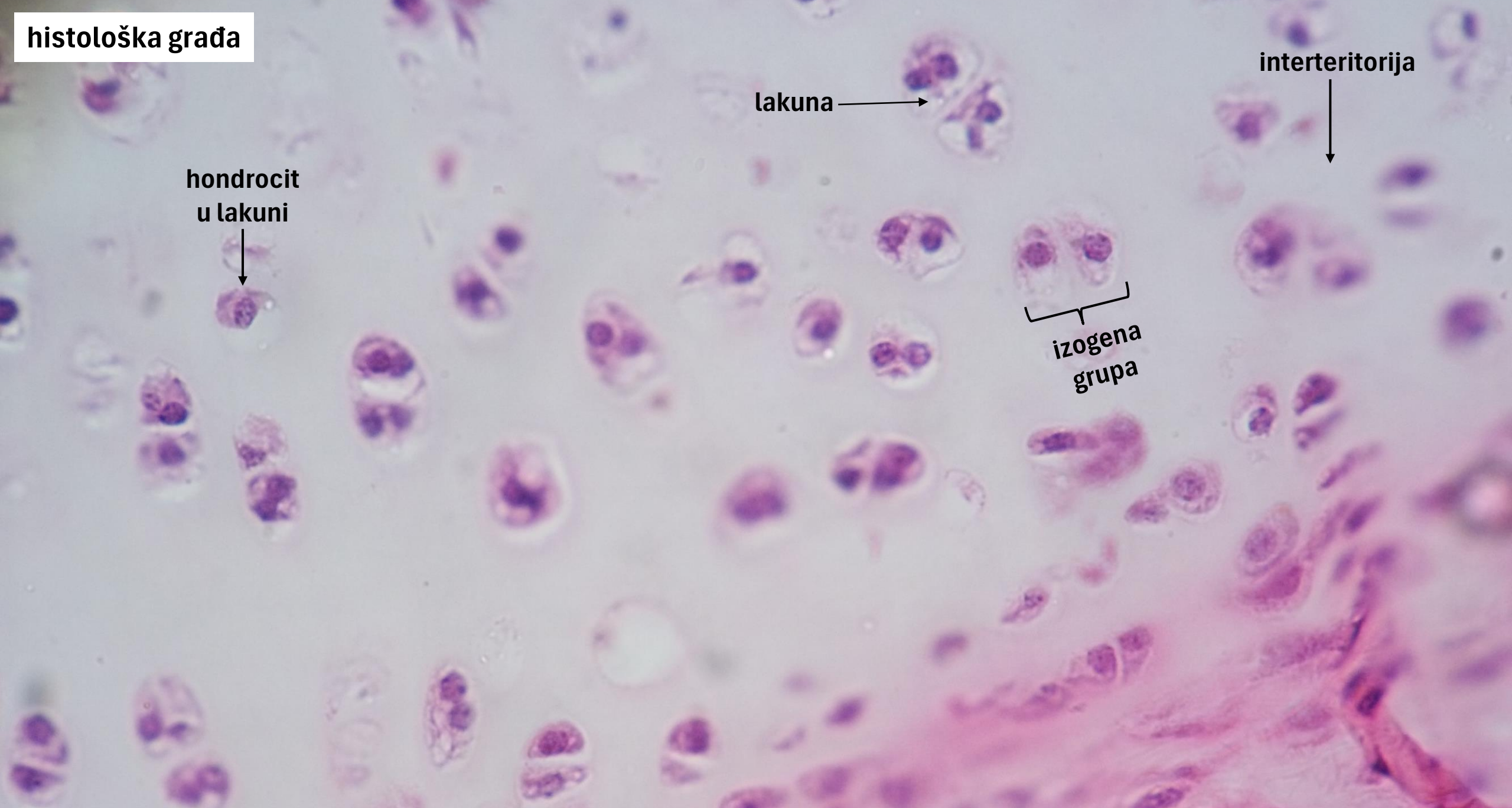materijal za laboratorijske vježbe



1) Hijalina hrskavica



histološka građa



lakuna →

interteritorija ↓

hondrocit
u lakuni ↓

izogena
grupa

šema građe

hondrociti

interteritorija

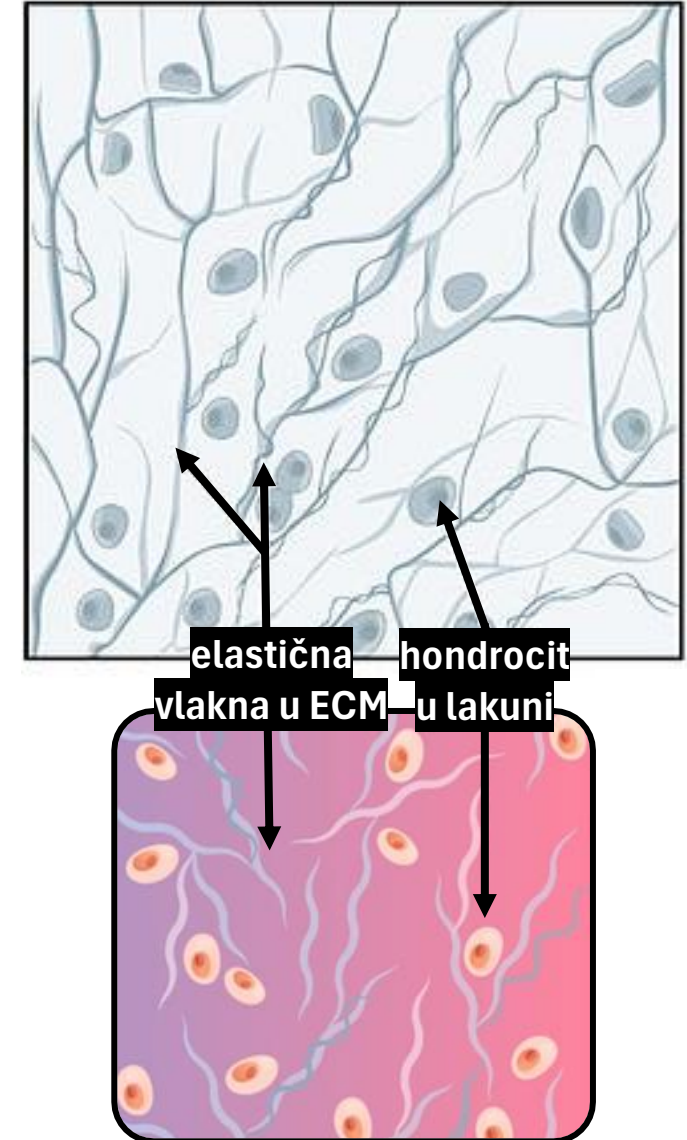
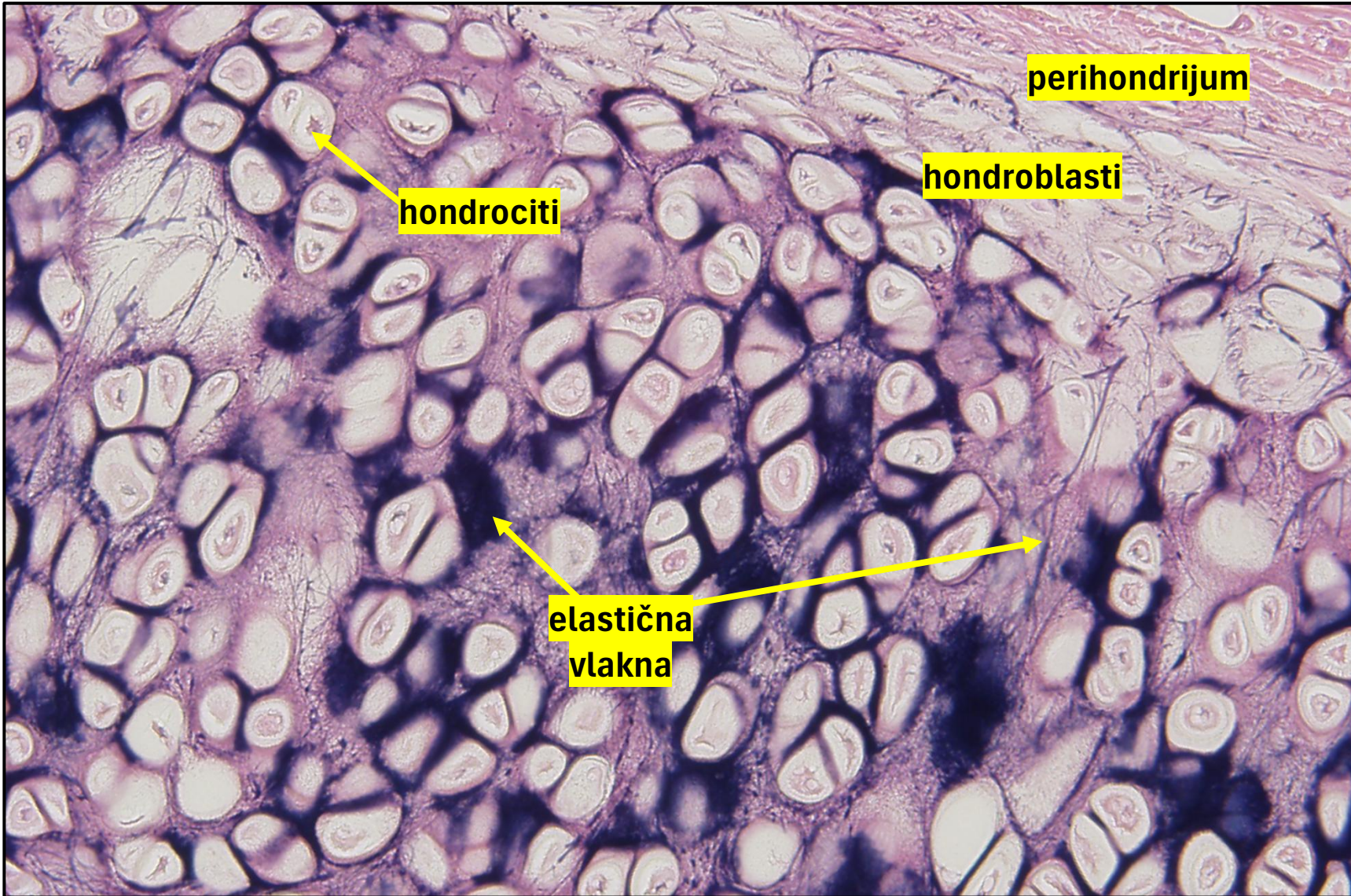
lakune

izogene grupe

jedro

teritorijalni matriks

2) Elastična hrskavica



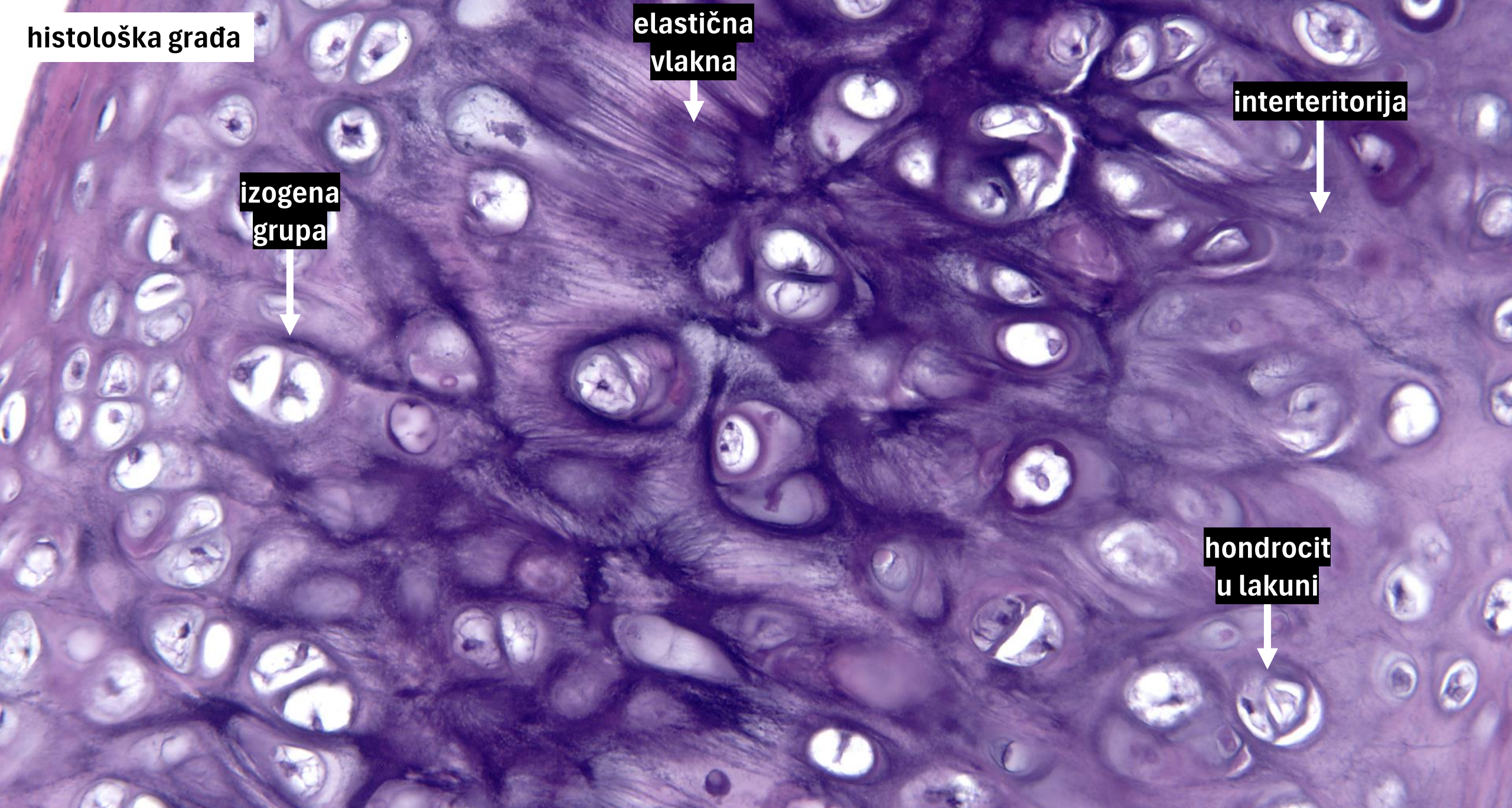
histološka građa

elastična
vlakna

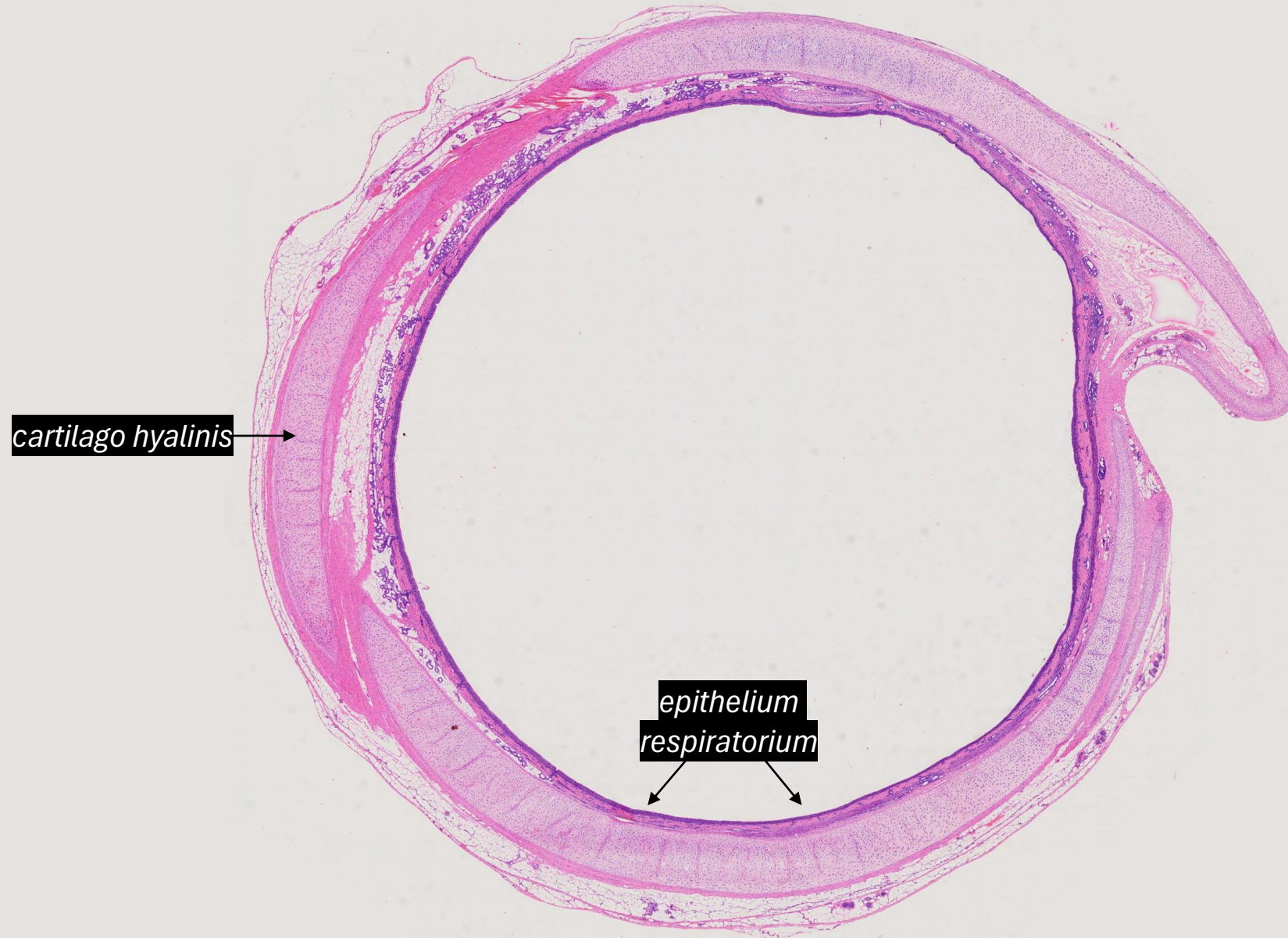interteritorija

izogena
grupa

hondrocit
u lakuni

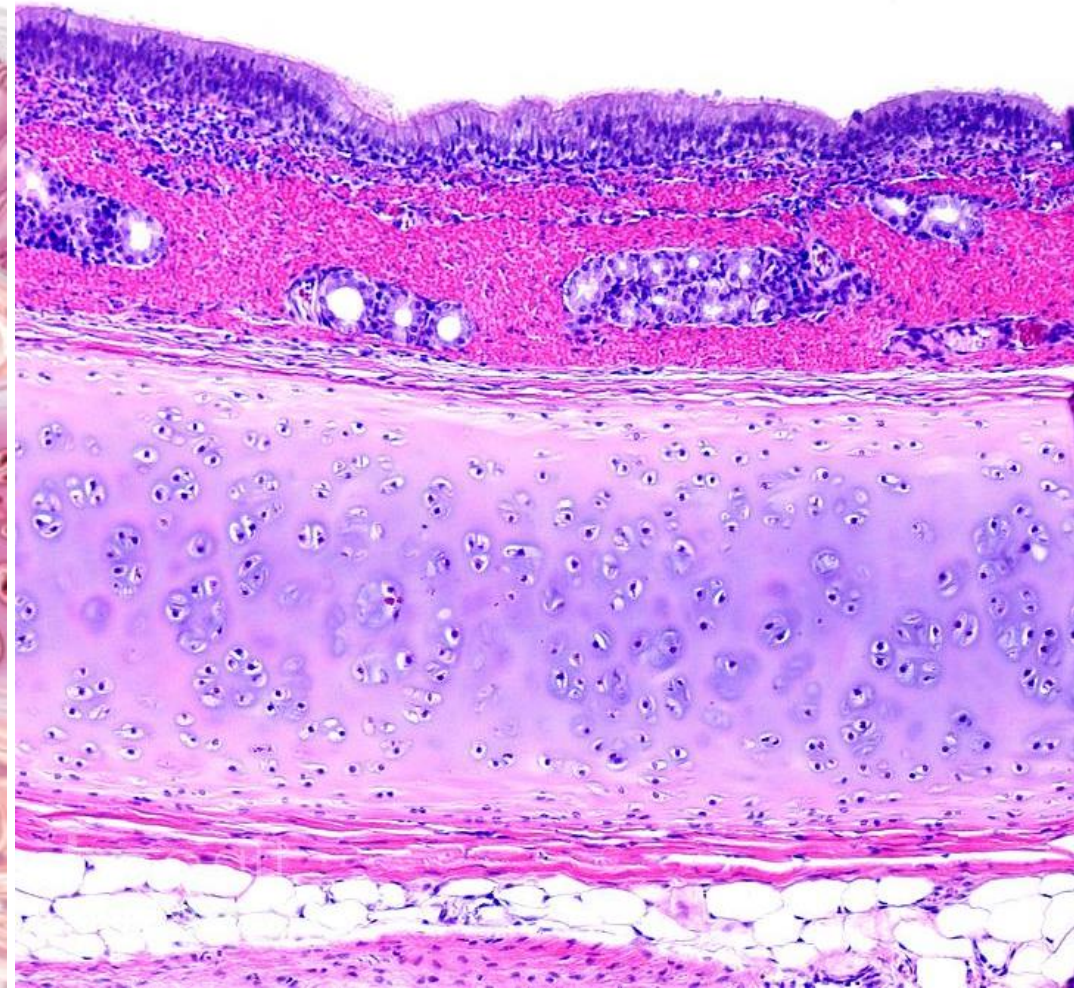
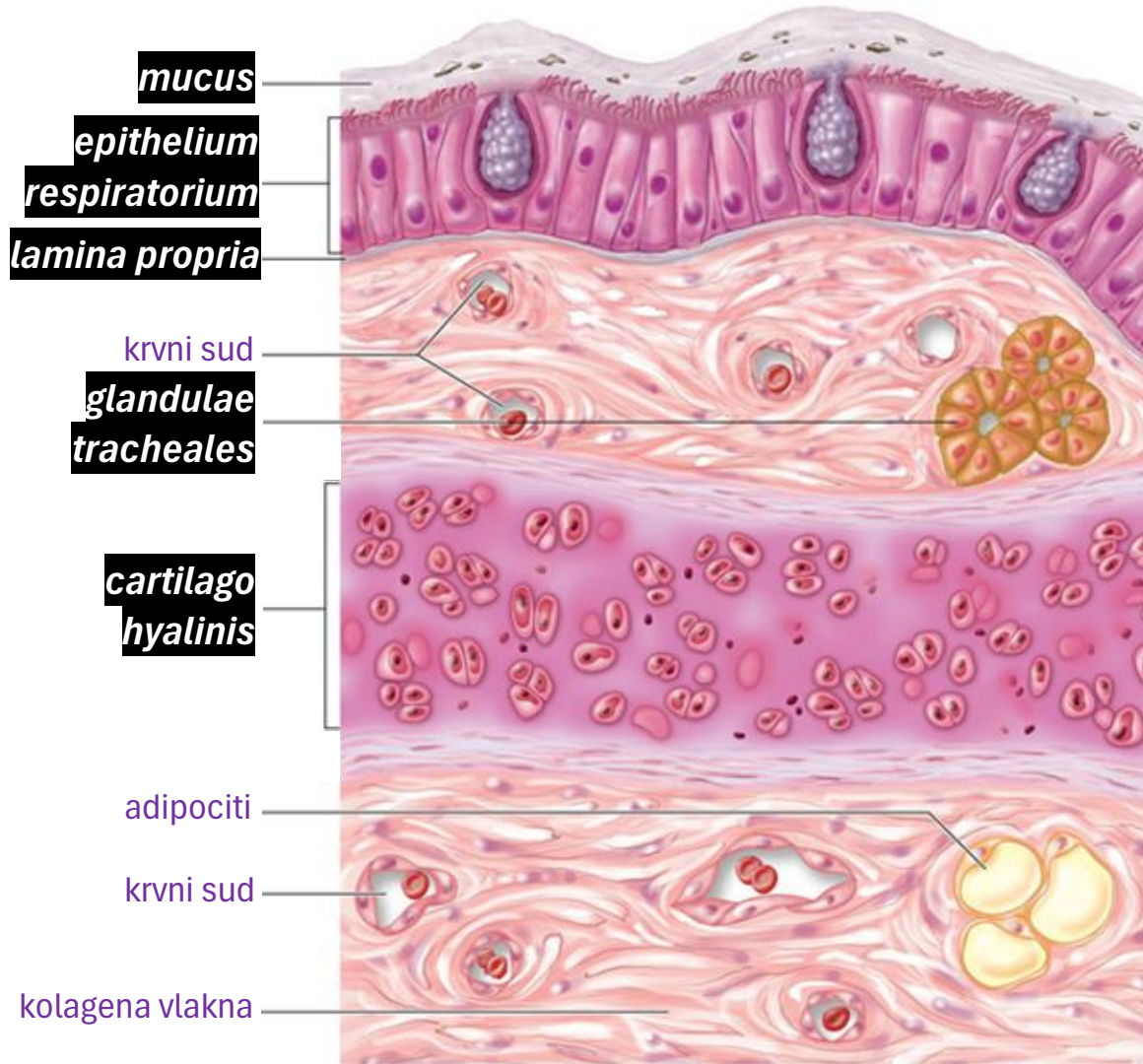


3) Epitelno i vezivno tkivo u dušniku



dušnik
(trachea)

Dušnik: histološka građa i šematski prikaz



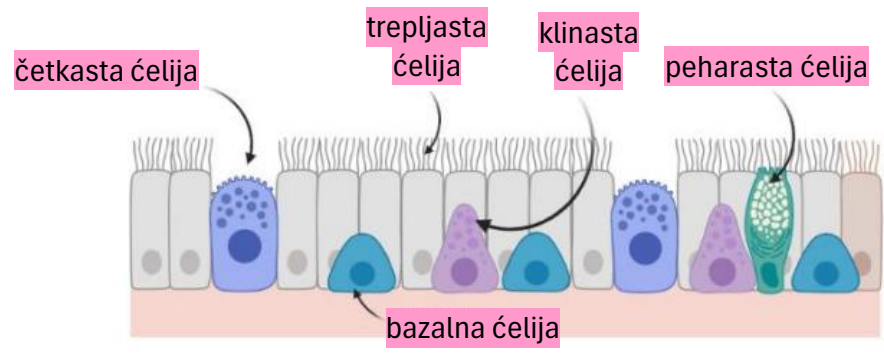
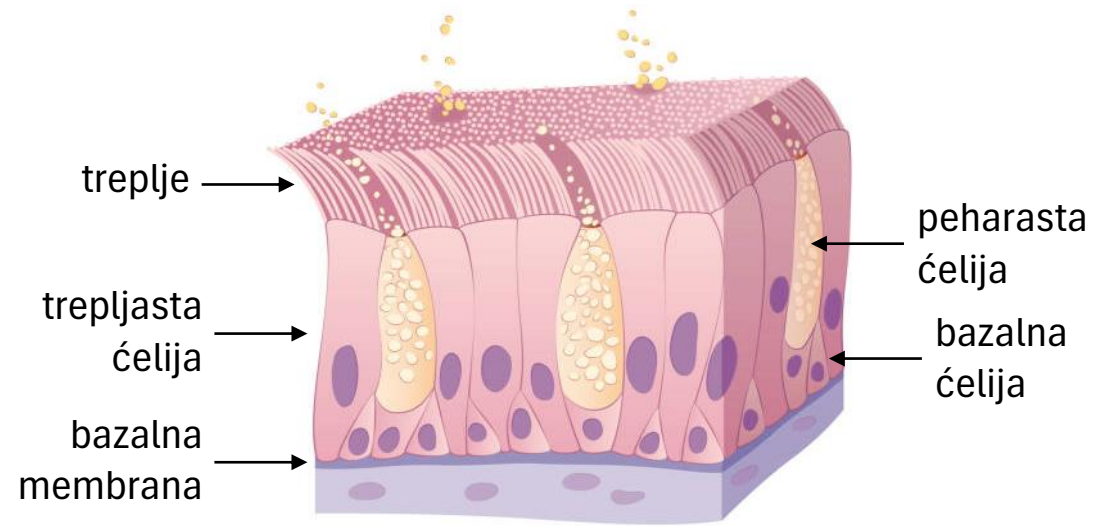
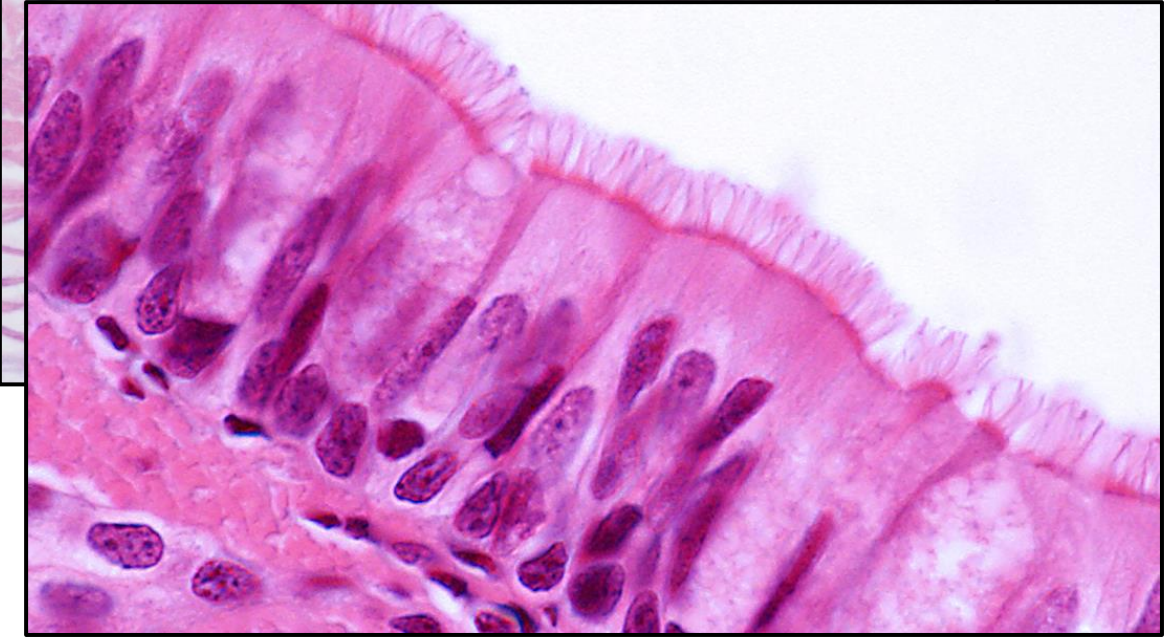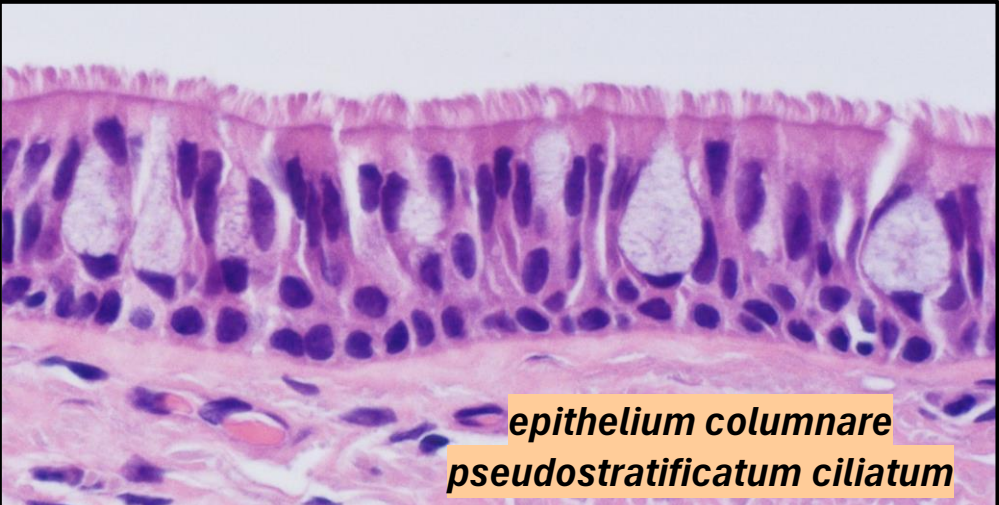tunica mucosa

tunica submucosa

tunica fibromusculo-cartilaginea

tunica adventitia

Pseudoslojeviti troredni epitel (trepljasti epitel)



Rastresito vezivno i hrskavičavo tkivo

