

9V: Vezivna tkiva

PREPARATI:

- 1) Bijelo masno tkivo
- 2) Mrko masno tkivo
- 3) Koštano tkivo
- 4) Razmaz krvi

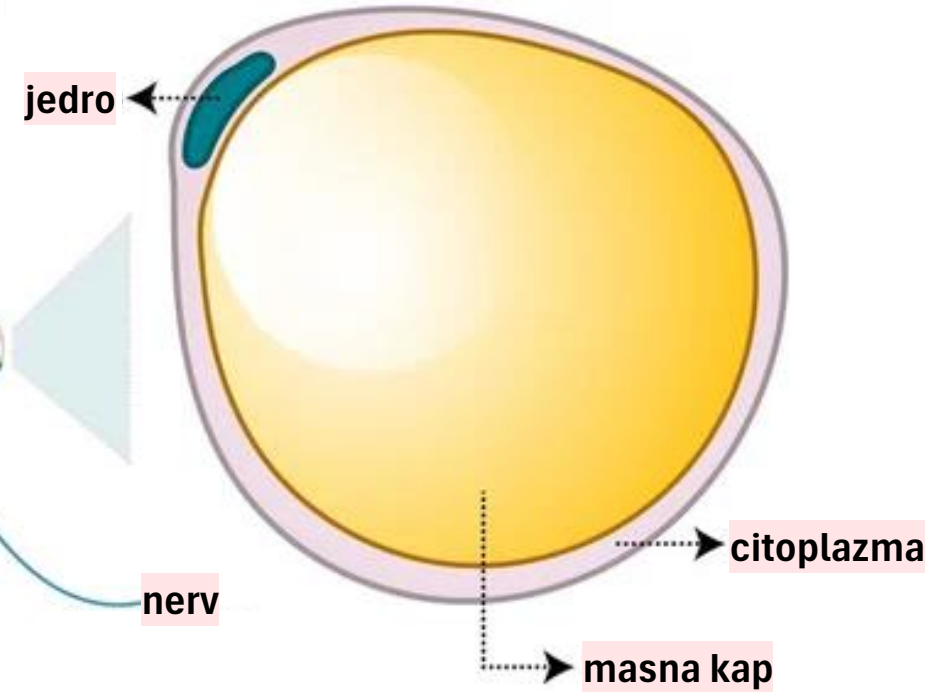
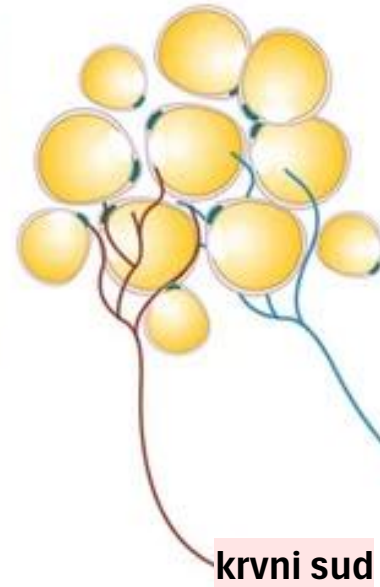

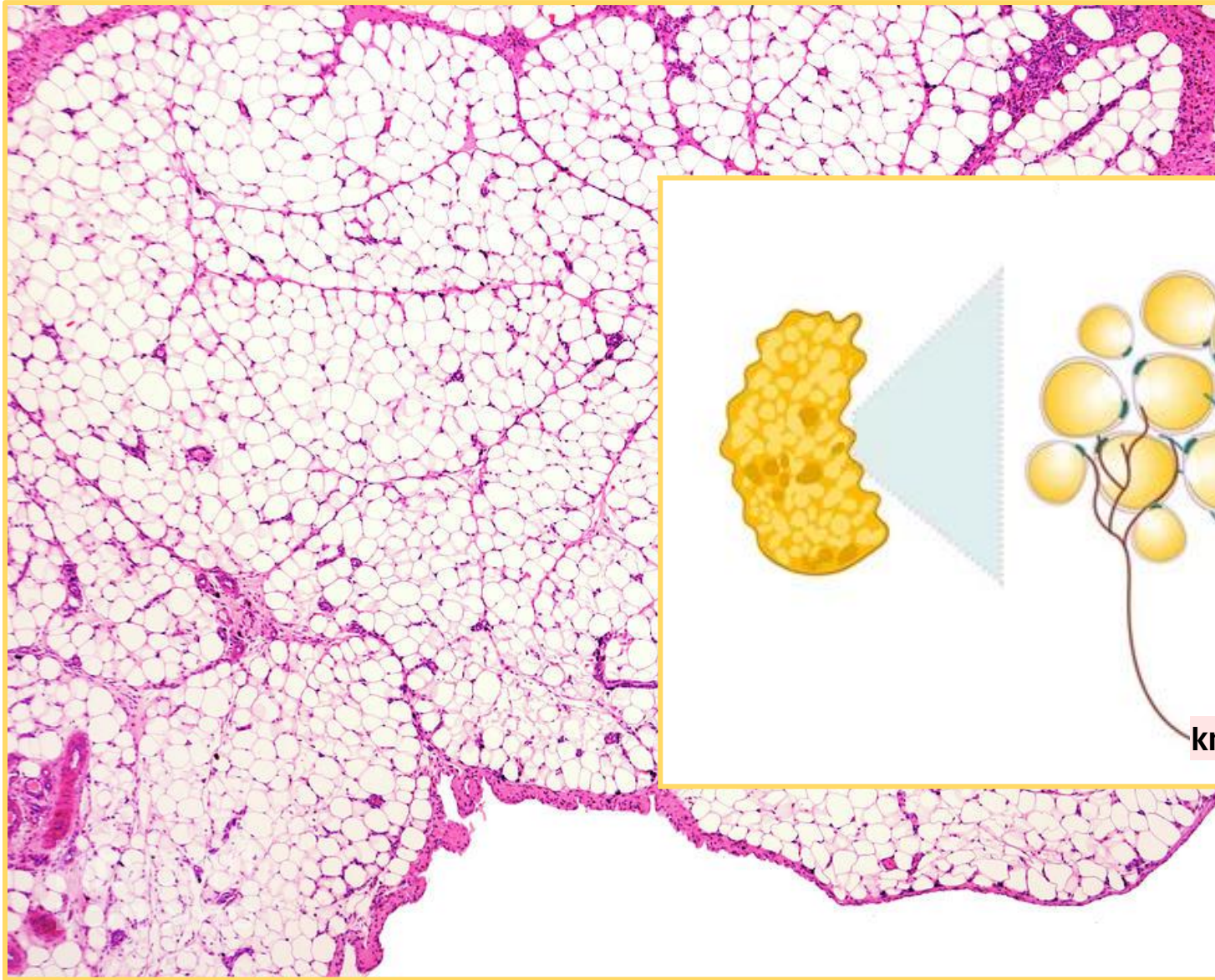
Mijat Božović

CITOLOGIJA I TKIVA

materijal za laboratorijske vježbe



1) Bijelo masno tkivo



textus adiposus albus

jedro →

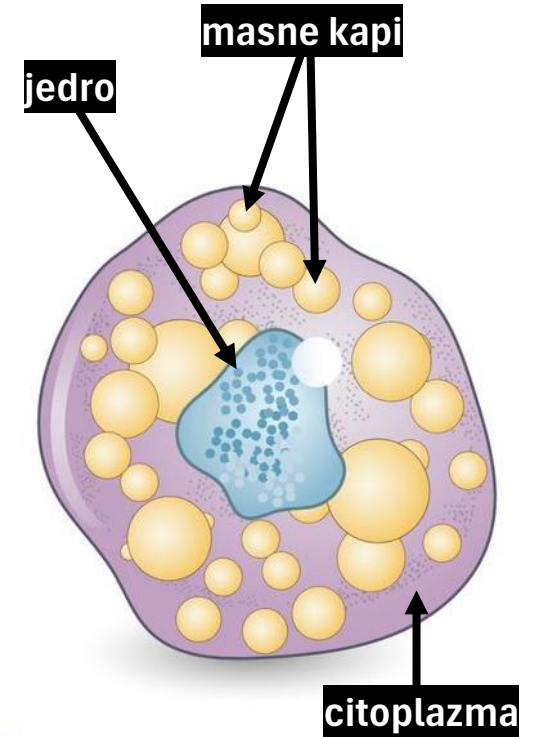
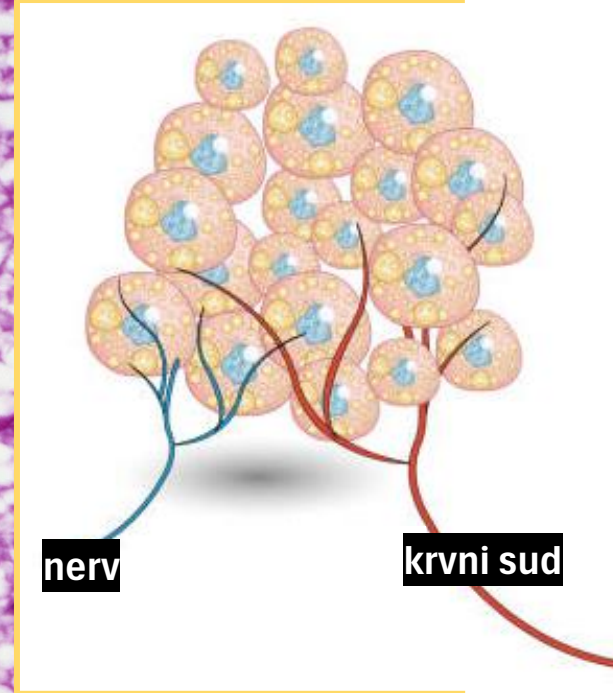
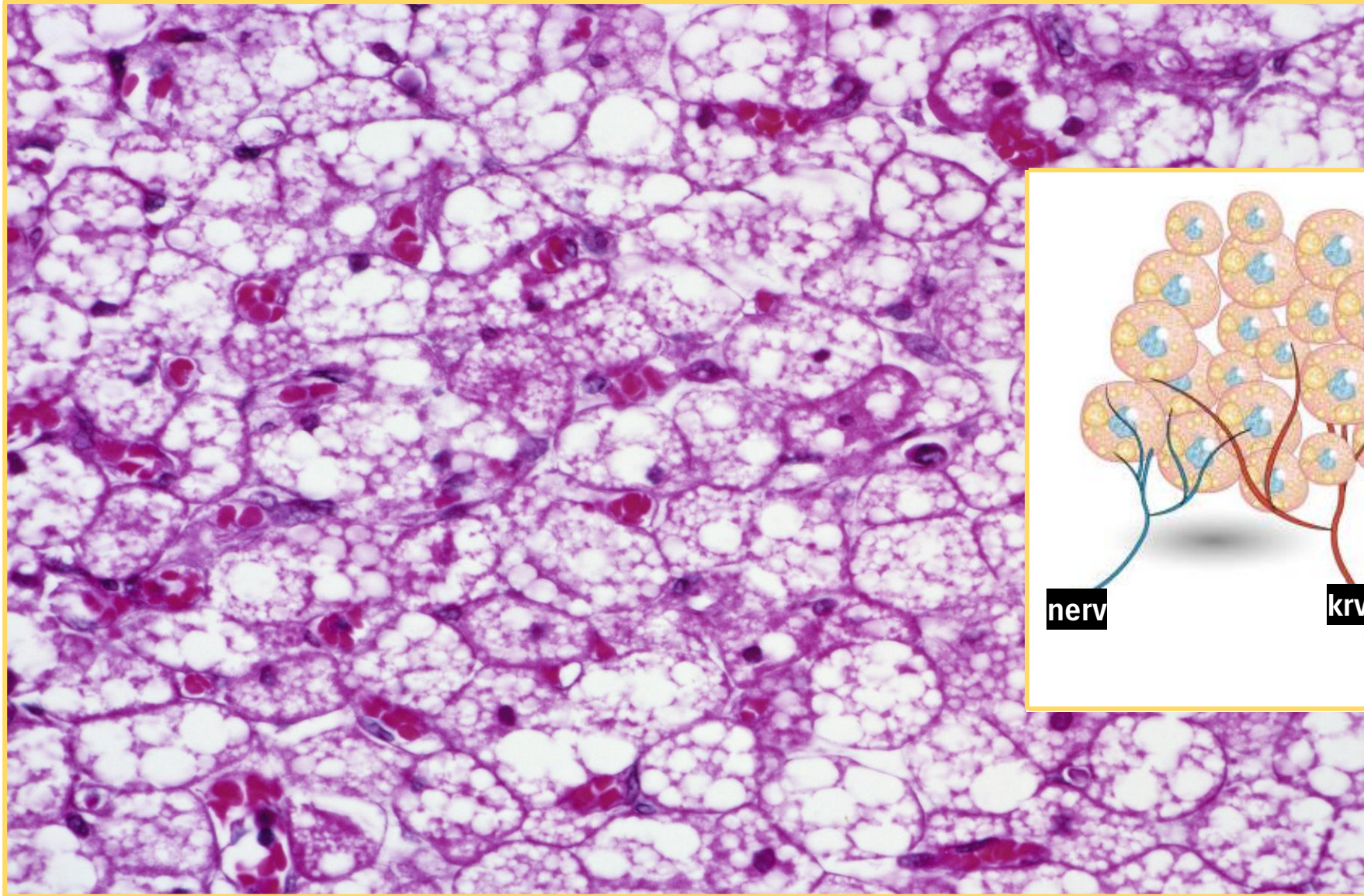
masna

kap

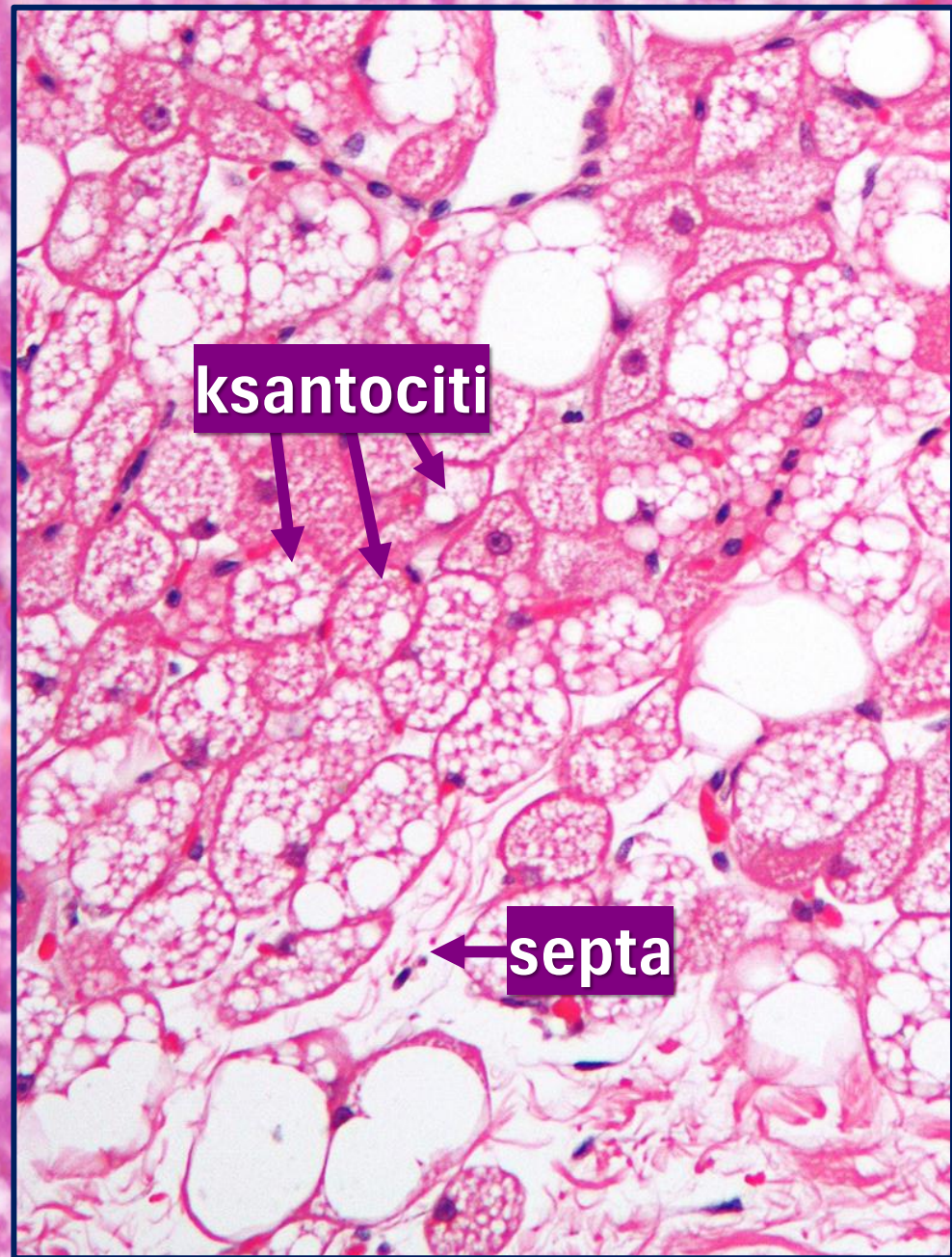
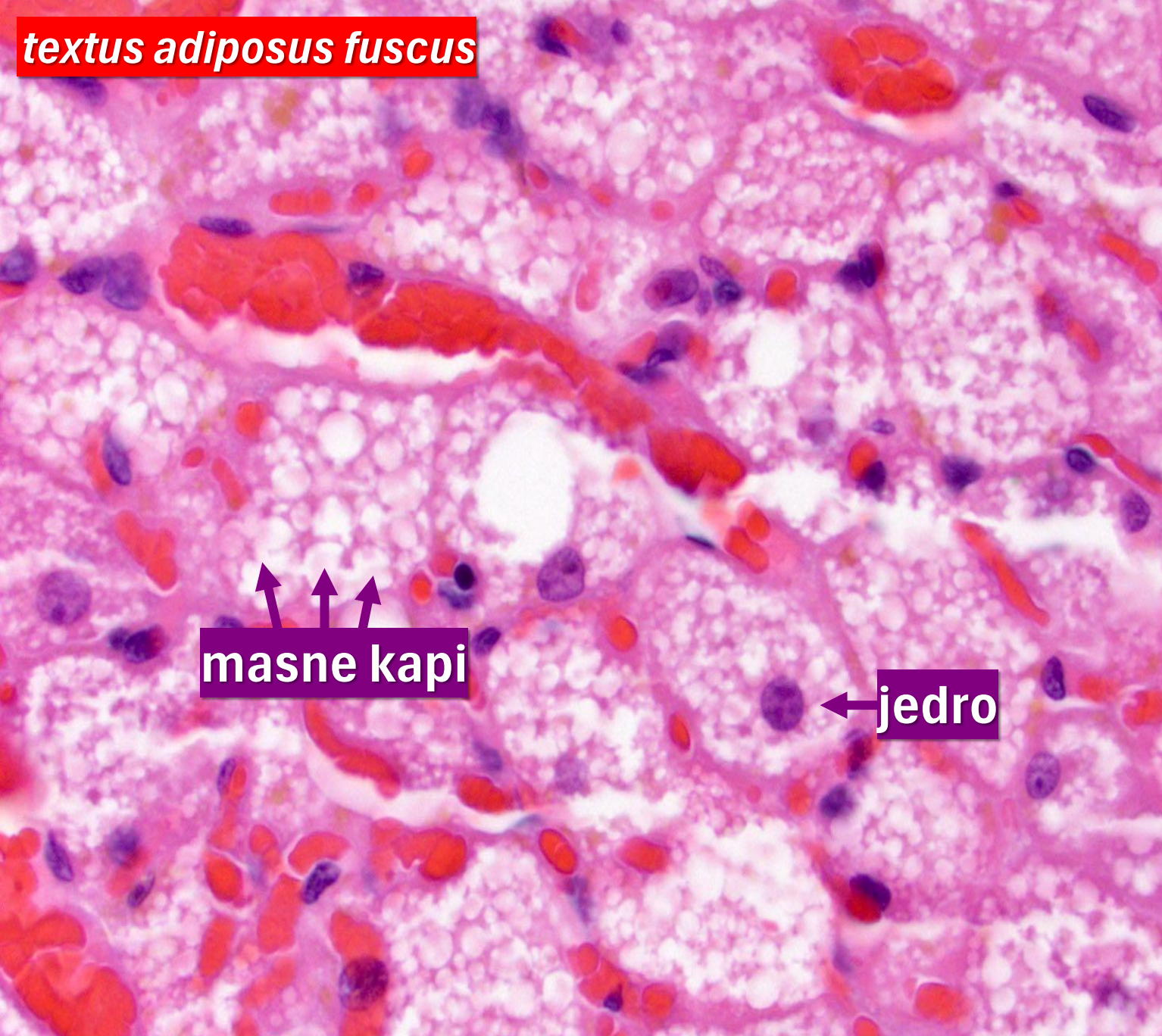
adipociti

septa

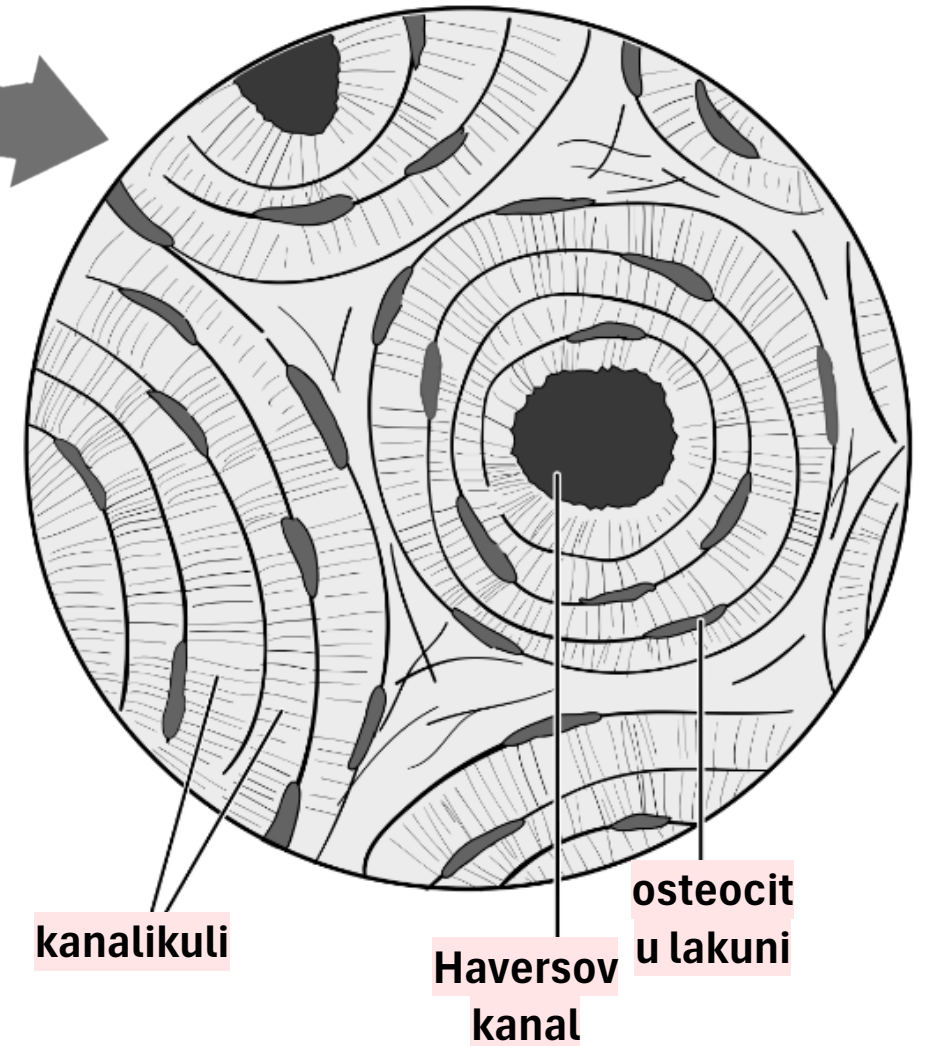
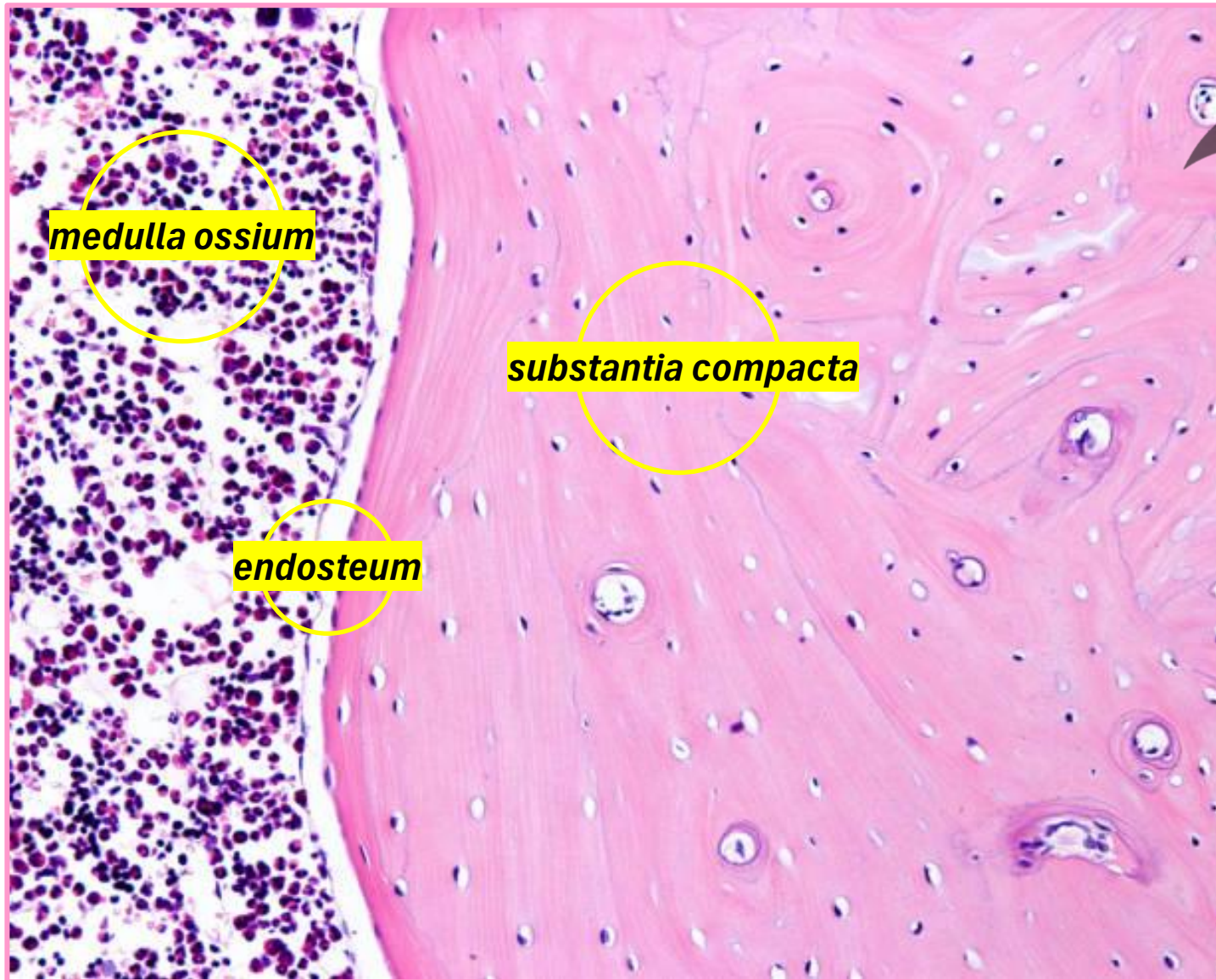
2) Mrko masno tkivo



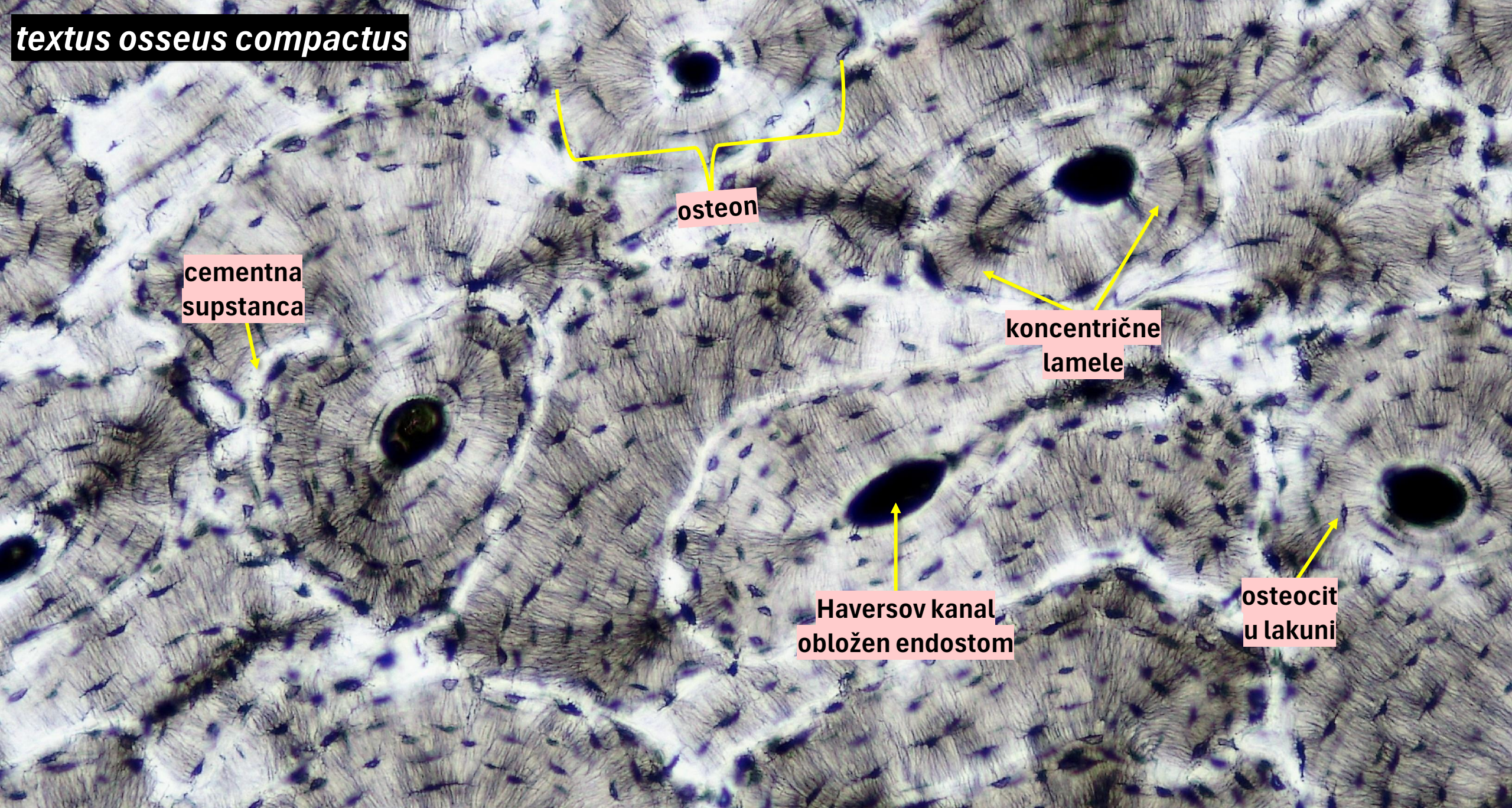
textus adiposus fuscus



3) Koštano tkivo



textus osseus compactus



osteon


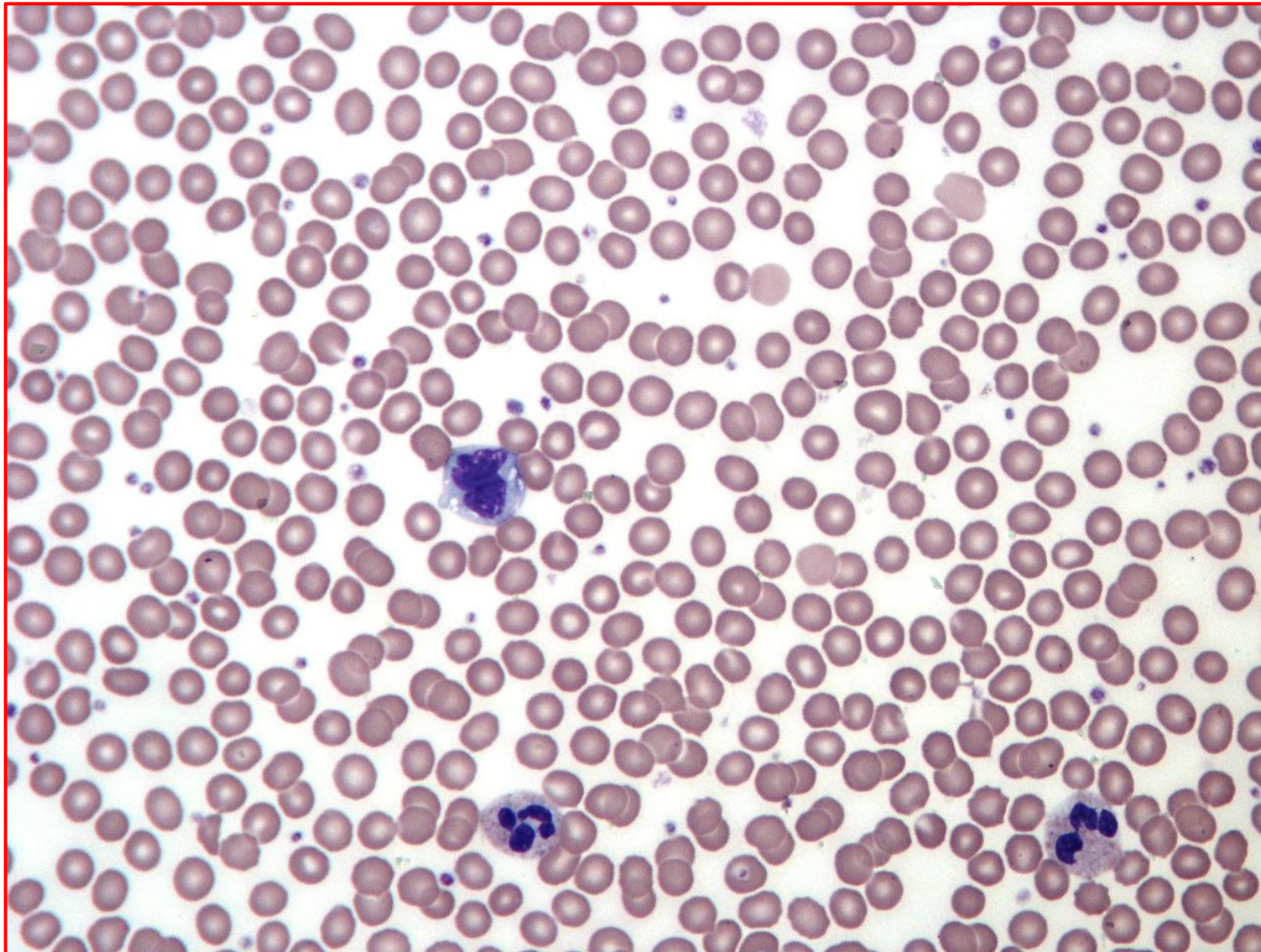
cementna
supstanca

koncentrične
lamelle

Haversov kanal
obložen endostom

osteocit
u lakuni

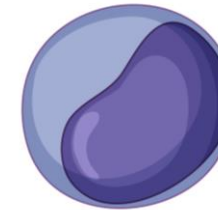
4) Razmaz krvi



eritrociti



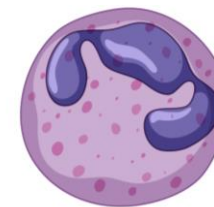
trombociti



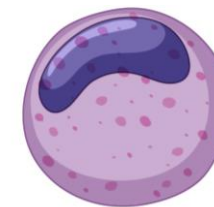
limfocit



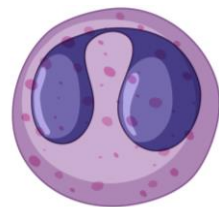
monocit



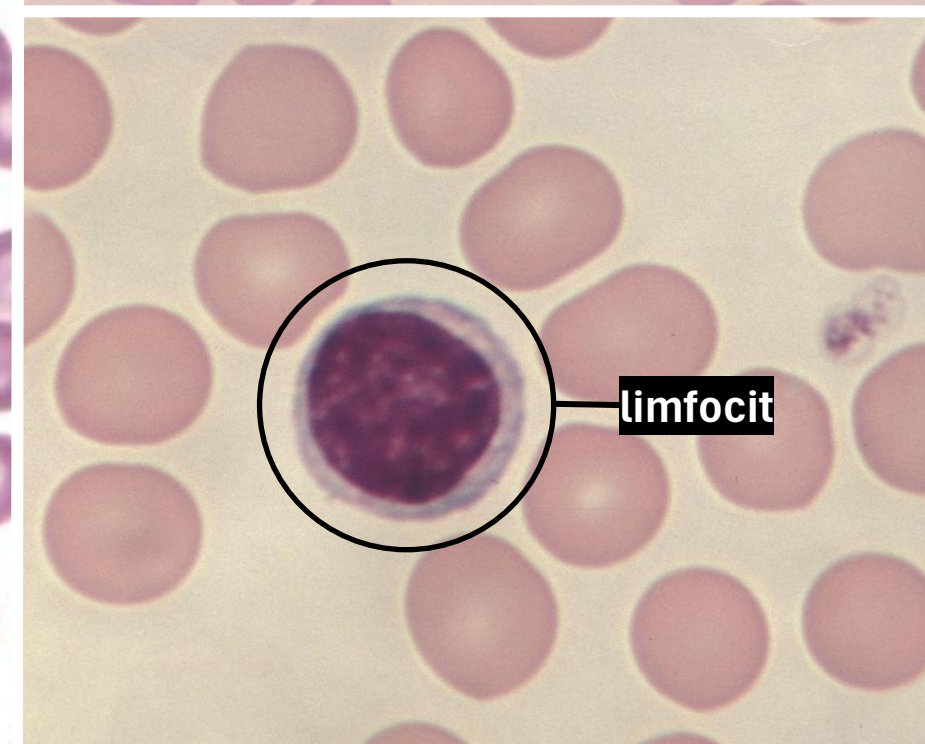
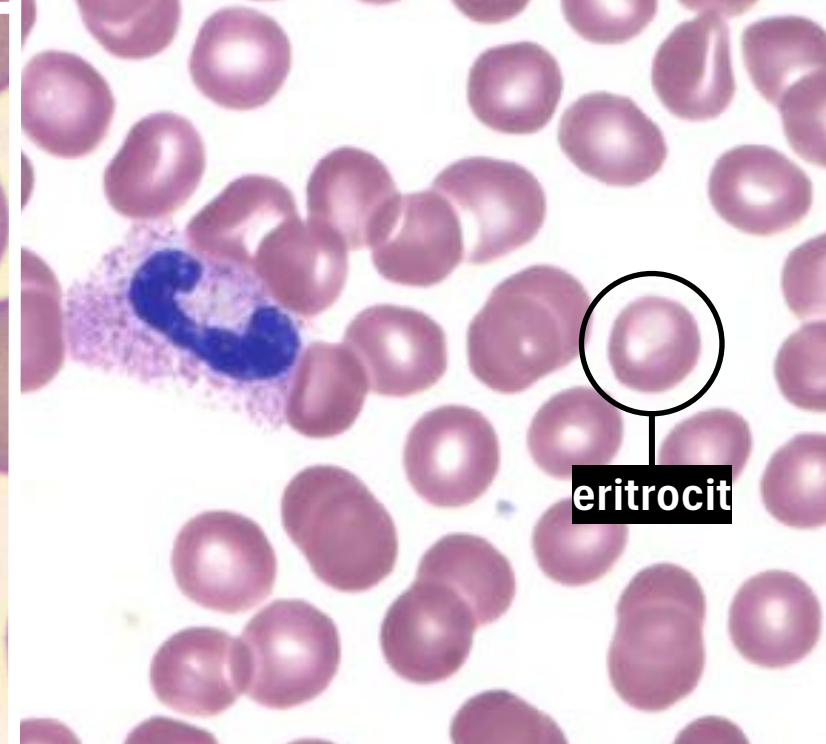
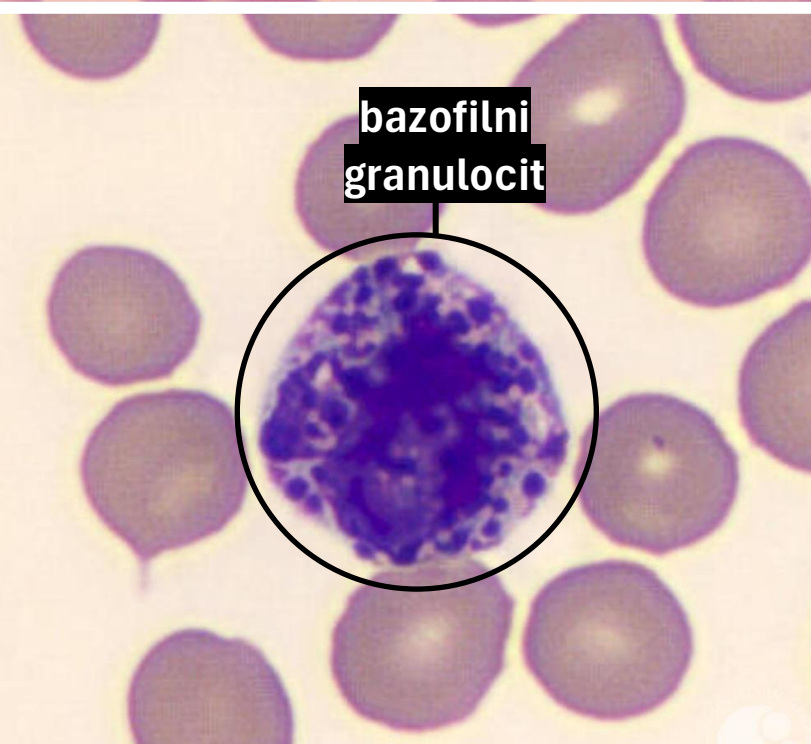
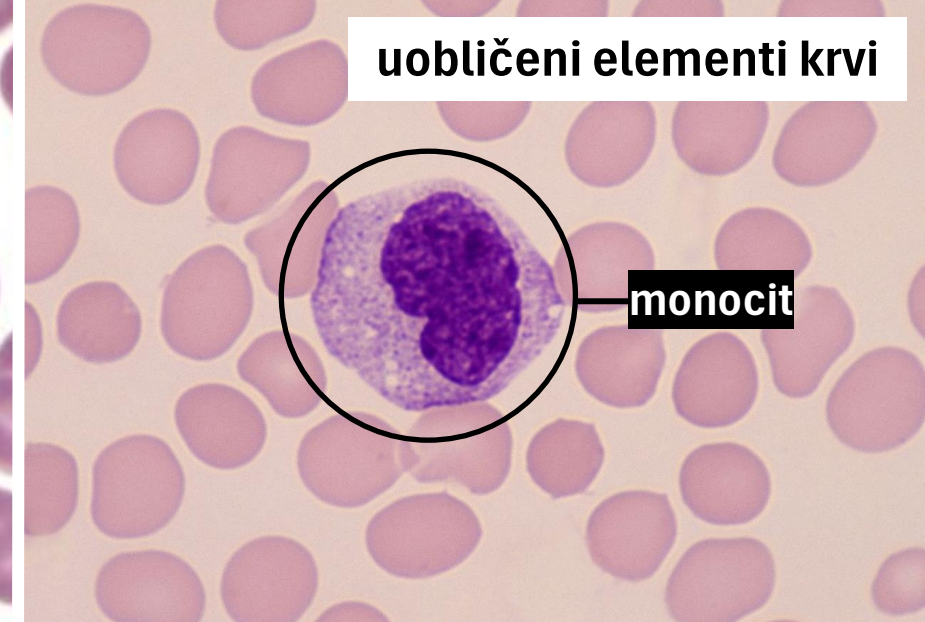
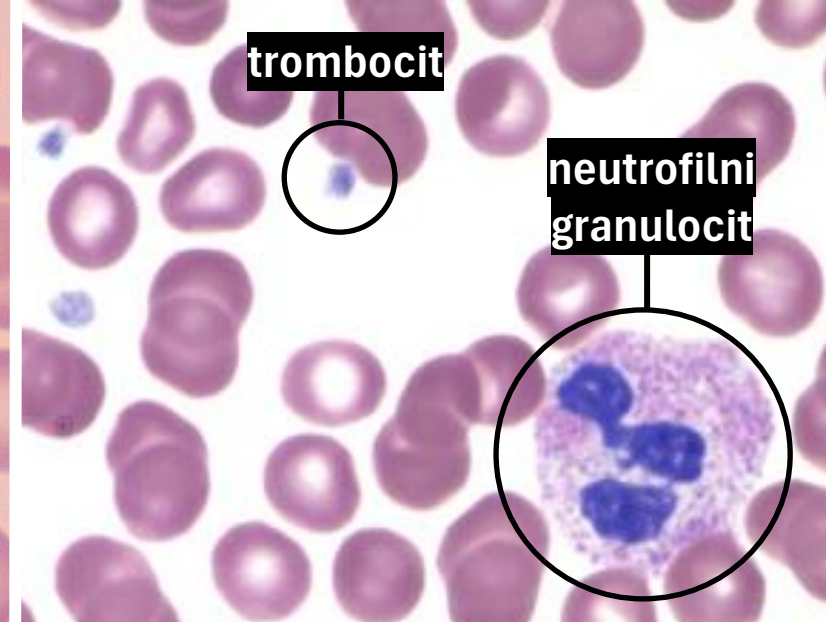
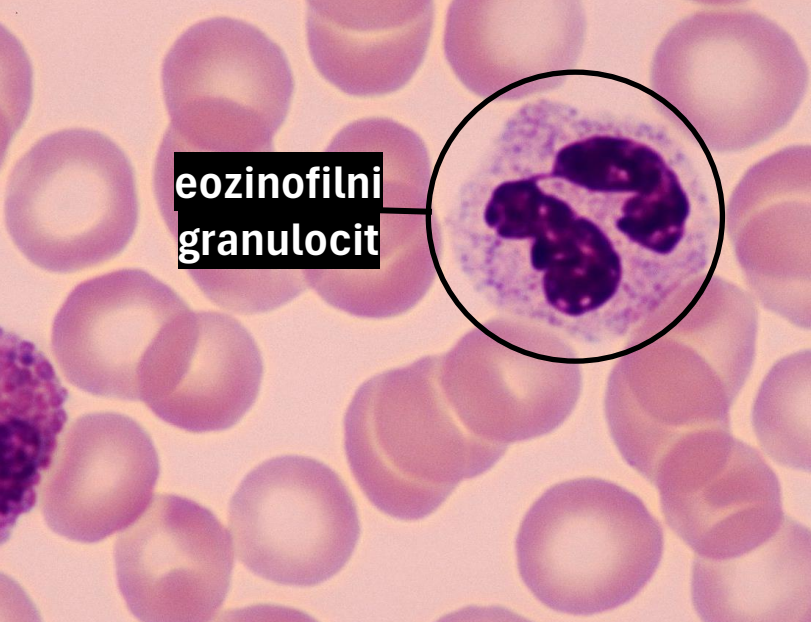
**neutrofilni
granulocit**



**bazofilni
granulocit**



**eozinofilni
granulocit**



uobličeni elementi krvi

